Questions from MKSAP 18 Complete

An ACP Chapter Education Resource

ACP®
American College of Physicians
Leading Internal Medicine, Improving Lives

Content Curation Disclosure

The following questions were chosen for Chapter use from MKSAP 18 Complete by:

Davoren Chick, MD, FACP
Senior Vice President
ACP Medical Education

Dr. Chick has nothing to disclose.

All relevant relationships have been mitigated.

Faculty Disclosures

- *Paul Kunnath, MD and Stephen Fuest, MD have no relevant relationships to disclose.*

Audience Response System

Join in the fun!

Take out your phone, open the camera app, hold the phone up so you can see this QR code. Click the link that appears.

OR, type in this link to your internet browser if using a computer:

https://we.dialog.live/FCM-KZZ

Audience Response Test

QUESTION 1

- A 47-year-old man is evaluated for a 2-day history of cough productive of small amounts of yellow sputum, as well as sinus congestion, frontal headache, rhinorrhea, and malaise.
- He has had no fevers, chest pain, or shortness of breath.
- Medical history is otherwise unremarkable.

QUESTION 1

- On physical examination, vital signs are normal. There is tenderness over the maxillary sinuses bilaterally. The nasal mucosa is diffusely edematous with moderate amounts of clear discharge.
- Pharyngeal examination reveals erythema without tonsillar exudate. The tympanic membranes appear normal. No cervical lymphadenopathy is noted.
- The remainder of the examination is normal.

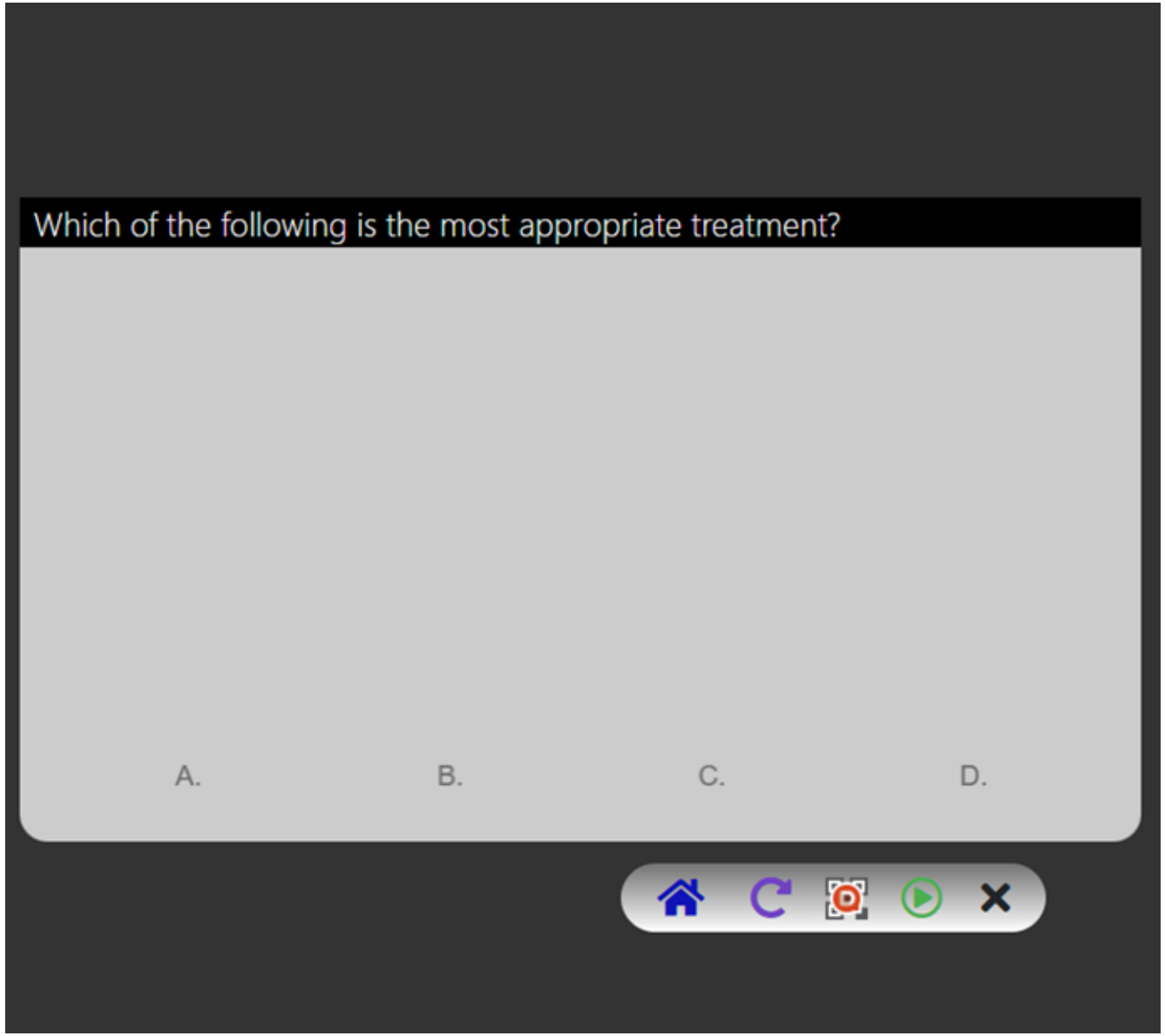

QUESTION 1

- **Which of the following is the most appropriate treatment?**

A. Amoxicillin

B. Codeine

C. Inhaled albuterol

D. Intranasal fluticasone

QUESTION 1

- **Which of the following is the most appropriate treatment?**

A. Amoxicillin

B. Codeine

C. Inhaled albuterol

D. **Intranasal fluticasone**

QUESTION 1

- **Diagnosis:**
  - Acute rhinosinusitis, upper airway cough
- **Which of the following is the most appropriate treatment?**

A. Amoxicillin: avoid due to lack of benefit and known harms

B. Codeine: avoid unless cough is refractory

C. Inhaled albuterol: if signs/symptoms of bronchospasm

D. **Intranasal fluticasone**

QUESTION 1

- **Diagnosis:**
  - Acute rhinosinusitis, upper airway cough
- **Evidence: symptom resolution at 21 days**

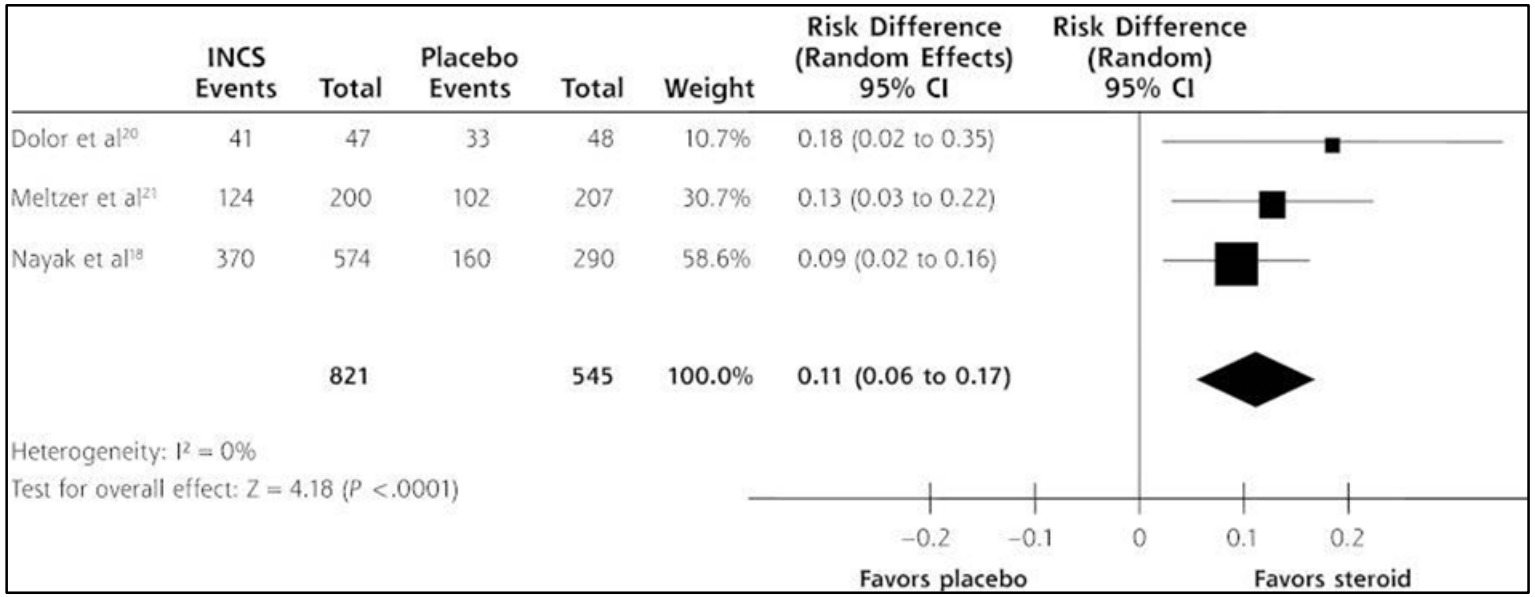

	INCS Events	Total	Placebo Events	Total	Weight	Risk Difference (Random Effects) 95% CI
Dolor et al[20]	41	47	33	48	10.7%	0.18 (0.02 to 0.35)
Meltzer et al[21]	124	200	102	207	30.7%	0.13 (0.03 to 0.22)
Nayak et al[18]	370	574	160	290	58.6%	0.09 (0.02 to 0.16)
		821		**545**	**100.0%**	**0.11 (0.06 to 0.17)**

Heterogeneity: $I^2 = 0\%$

Test for overall effect: $Z = 4.18$ ($P < .0001$)

Hayward, Gail et al. "Intranasal corticosteroids in management of acute sinusitis: a systematic review and meta-analysis." *Annals of family medicine* vol. 10,3 (2012): 241-9.

QUESTION 1

- **Educational Objective:**
  - Treat cough due to acute rhinosinusitis.

- **Key Point:**
  - Acute rhinosinusitis may be treated symptomatically with analgesics and intranasal glucocorticoids; antibiotics are not recommended without clearly established bacterial infection.

QUESTION 2

- A 66-year-old man is evaluated in the hospital following ST-elevation myocardial infarction treated with primary percutaneous coronary intervention of the left anterior descending artery 4 days ago.
- His initial presentation was complicated by the presence of heart failure and pulmonary edema.

QUESTION 2

- He is asymptomatic and ambulating, and he is nearly ready for discharge.
- Medical history is significant for hyperlipidemia, type 2 diabetes mellitus, and hypertension.
- Medications are aspirin, prasugrel, lisinopril, carvedilol, atorvastatin, and basal and prandial insulin.

QUESTION 2

- On physical examination, vital signs are normal. Oxygen saturation is 99% breathing ambient air. The remainder of the examination is unremarkable.
- Laboratory studies are significant for a serum creatinine level of 1.0 mg/dL (88.4 µmol/L) and a serum potassium level of 3.7 mEq/L (3.7 mmol/L).
- An echocardiogram shows a left ventricular ejection fraction of 35%.

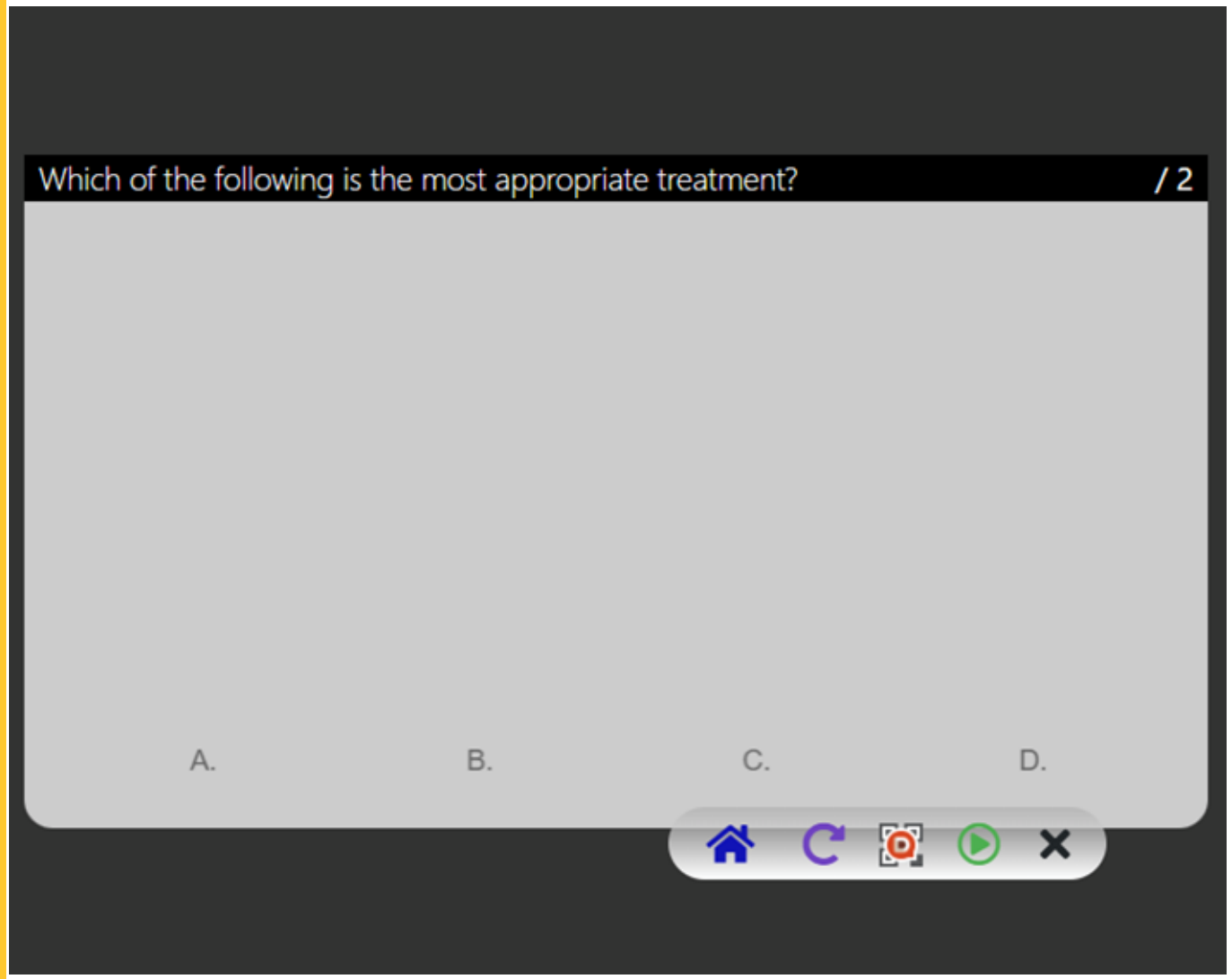

QUESTION 2

- **Which of the following is the most appropriate treatment?**

A. Eplerenone

B. Isosorbide mononitrate

C. Valsartan

D. Warfarin

QUESTION 2

- **Which of the following is the most appropriate treatment?**

A. **Eplerenone**

B. Isosorbide mononitrate

C. Valsartan

D. Warfarin

QUESTION 2

GDMT for post-myocardial infarction LV dysfunction

QUESTION 2

GDMT for post-myocardial infarction LV dysfunction

Aldosterone antagonists

- EPHESUS trial in NEJM in 2003
- RCT, double-blind, ~3300 in eplerenone or placebo groups
- Within 3-14 days of AMI with LVEF ≤ 40%
- Primary outcomes
  - Death from any cause
  - Death from CV cause, hospitalization for HF, AMI, CVA, VF

QUESTION 2

GDMT for post-myocardial infarction LV dysfunction

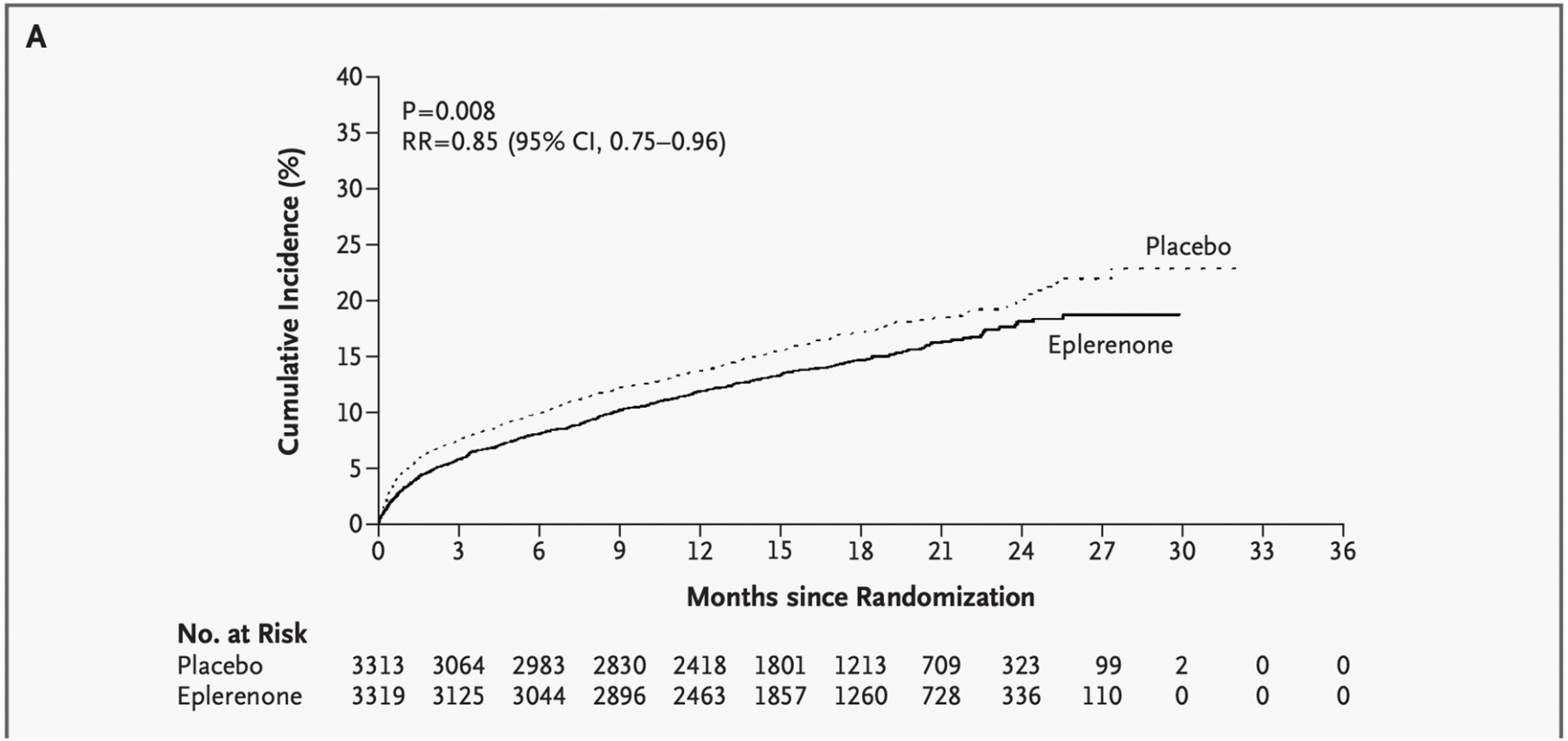

QUESTION 2

GDMT for post-myocardial infarction LV dysfunction

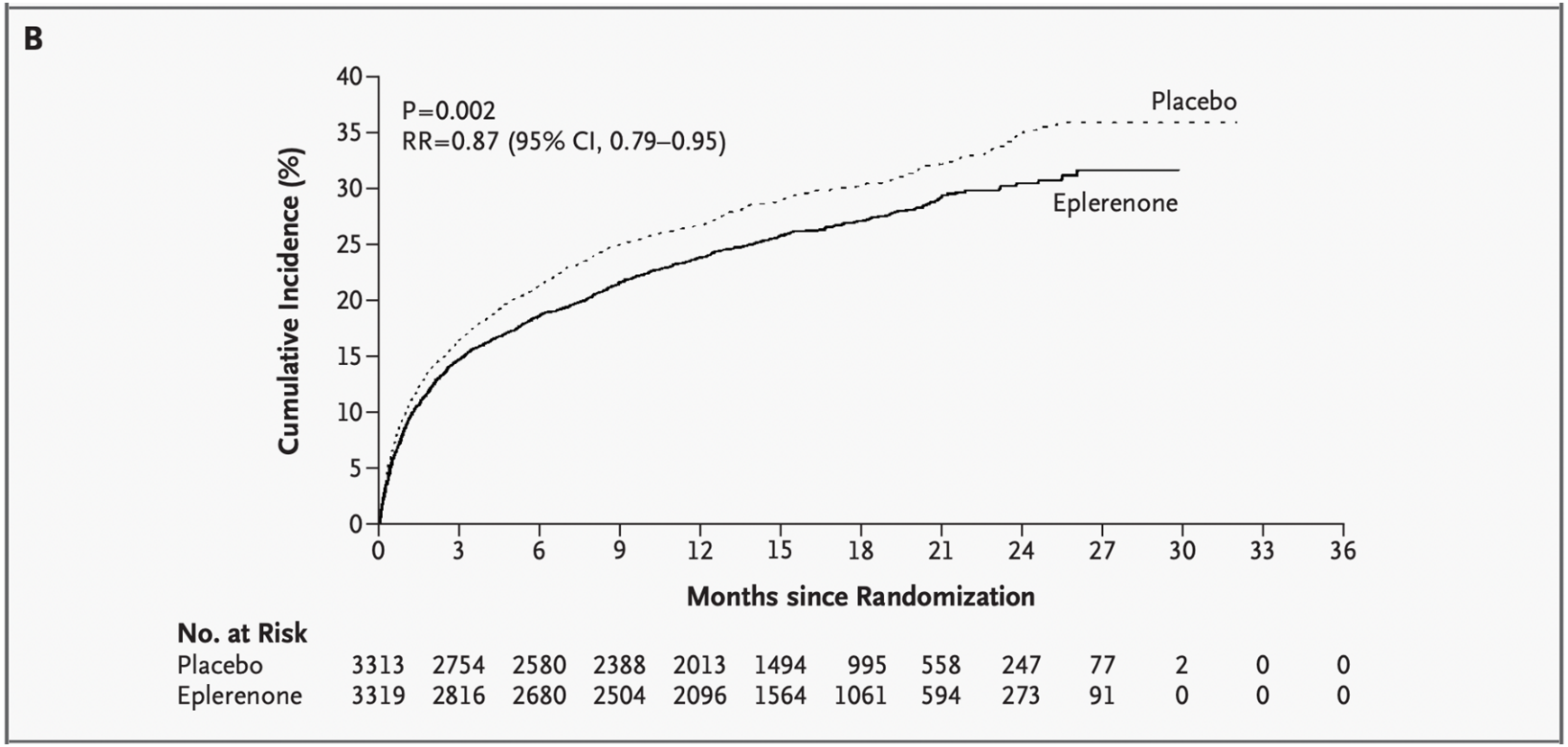

QUESTION 2

GDMT for post-myocardial infarction LV dysfunction

Isosorbide mononitrate

- Can be utilized for medical management of stable angina

QUESTION 2

GDMT for post-myocardial infarction LV dysfunction

ARB/ACE inhibitor

- Use ARB or ACE inhibitor but avoid combined use due to increase adverse effects

QUESTION 2

GDMT for post-myocardial infarction LV dysfunction

Anticoagulation

- Rivaroxaban has been studied at doses of 2.5-5.0 mg BID
- No conclusive studies for other anticoagulants

QUESTION 2

- **Educational Objective:**
  - Treat ST-elevation myocardial infarction complicated by heart failure.

- **Key Point:**
  - In patients with ST-elevation myocardial infarction, left ventricular ejection fraction of 40% or less, and either heart failure symptoms or diabetes mellitus, an aldosterone antagonist is recommended in addition to ACE inhibitor and β-blocker therapy.

QUESTION 3

- A 78-year-old man is evaluated for exertional dyspnea.
- He was previously asymptomatic, but 4 months ago he began having shortness of breath during moderate levels of activity. The dyspnea dissipates with rest.
- He is otherwise healthy and takes no medications.

QUESTION 3

- On physical examination, temperature is normal, supine blood pressure is 132/80 mm Hg, pulse rate is 80/min, and respiration rate is 22/min. The lungs are clear to auscultation.

- The carotid upstroke is delayed. There is a grade 3/6 late-peaking systolic murmur best heard at the base of the heart with radiation to both carotid arteries. S_1 is normal; the aortic component of S_2 is diminished.

QUESTION 3

- The remainder of the examination is unremarkable.

- An echocardiogram demonstrates a left ventricular ejection fraction of 65%. There is moderate aortic stenosis, with a mean gradient of 28 mm Hg and an aortic valve area of 1.5 cm^2.

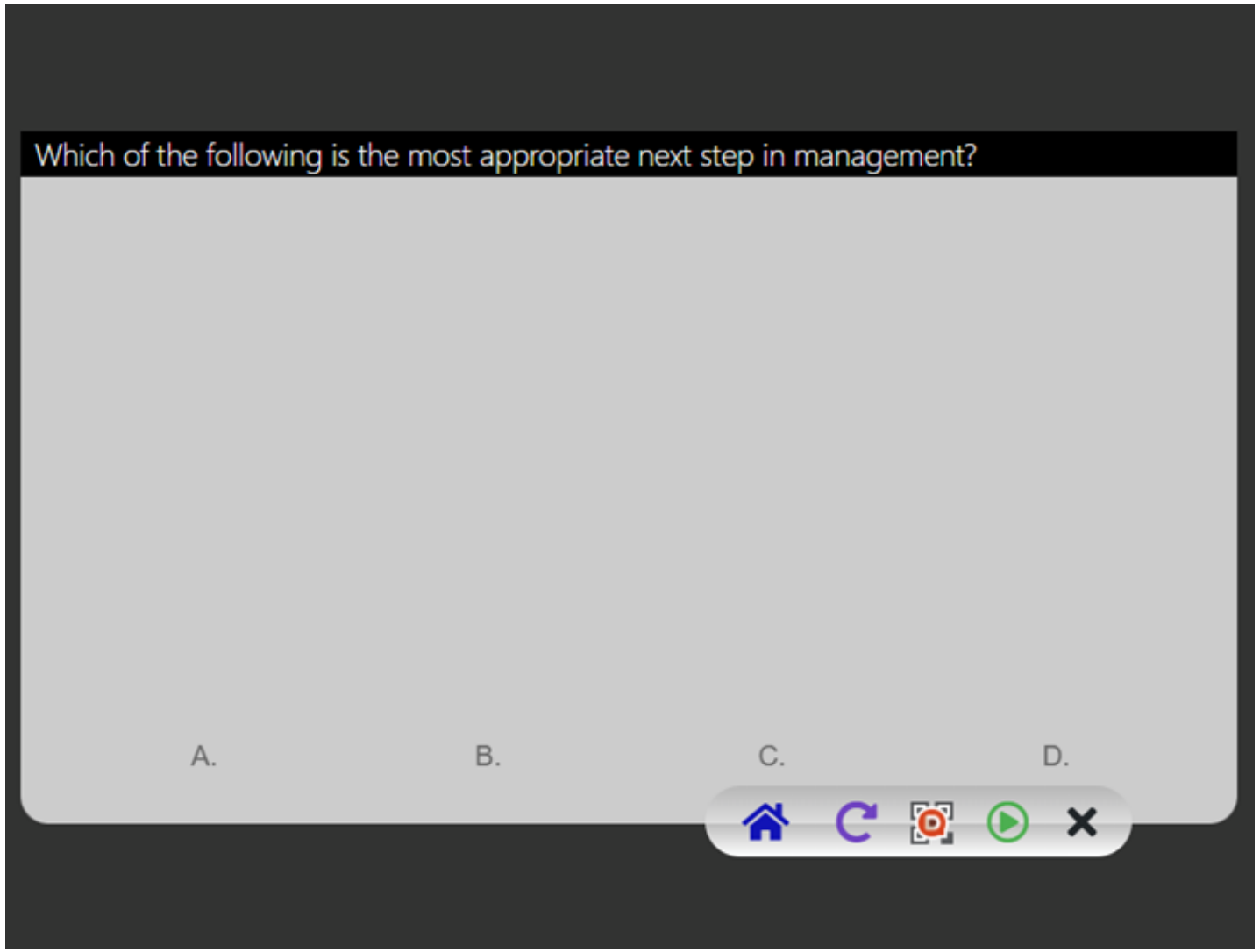

QUESTION 3

- **Which of the following is the most appropriate next step in management?**

A. Cardiac catheterization

B. Surgical aortic valve replacement

C. Transcatheter aortic valve replacement

D. Continued clinical observation

QUESTION 3

- **Which of the following is the most appropriate next step in management?**

A. **Cardiac catheterization**

B. Surgical aortic valve replacement

C. Transcatheter aortic valve replacement

D. Continued clinical observation

QUESTION 3

- **Diagnosis:**
  - Aortic s
- **Which of t** **eatment?**

A. **Cardiac**

B. Surgical ation if severe

C. Transcat SAVR

D. Continu mortality if severe

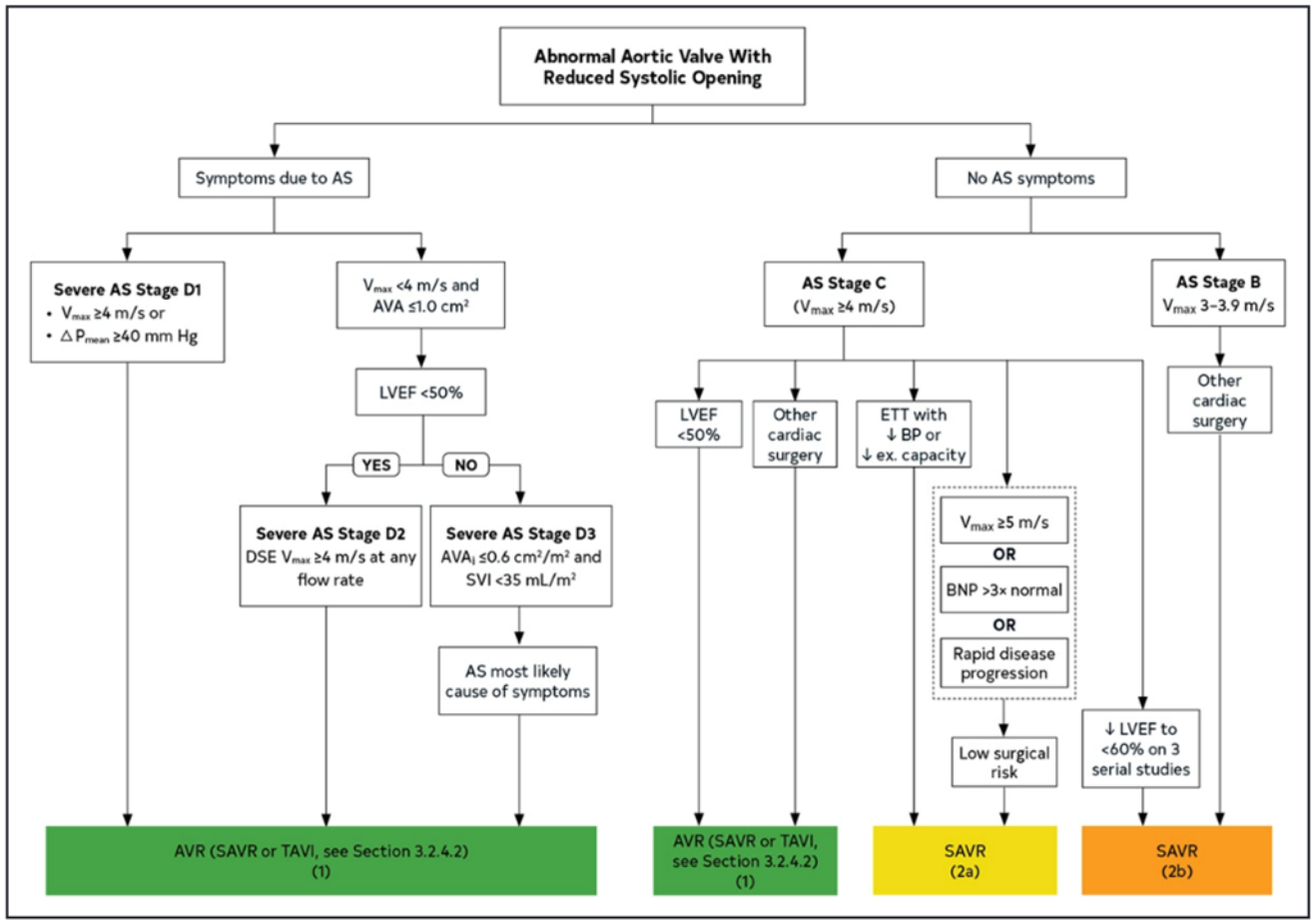

QUESTION 3

- **Diagnosis:**
  - Aortic stenosis: severe by exam, moderate by echo
- **Evidence: exam for aortic stenosis severity**

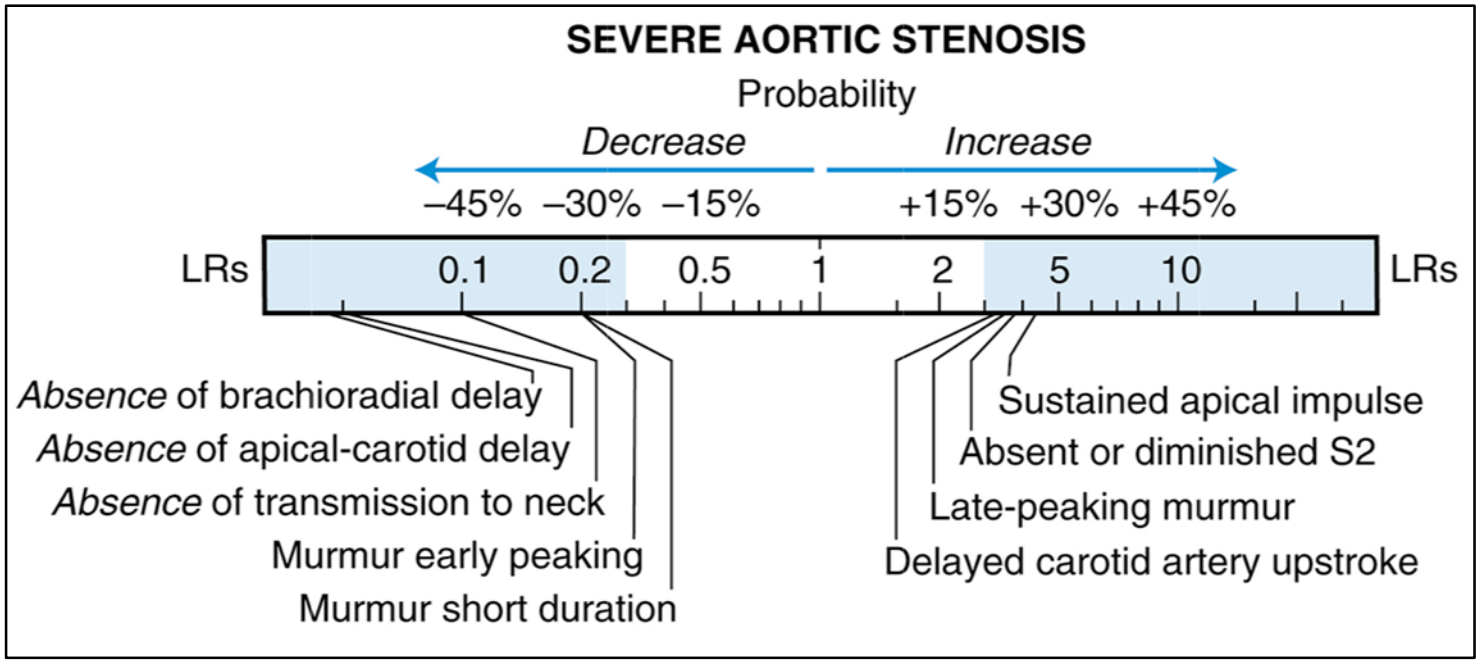

McGee. *Evidence-Based Physical Diagnosis*. Elsevier, 2018.

QUESTION 3

- **Educational Objective:**
  - Evaluate the severity of aortic stenosis with cardiac catheterization.

- **Key Point:**
  - In patients with symptoms of aortic stenosis and discrepancies between the physical examination and echocardiographic findings, the severity of stenosis should be established with cardiac catheterization before aortic valve replacement is performed.

Nishimura, Rick A et al. "2017 AHA/ACC Focused Update of the 2014 AHA/ACC Guideline for the Management of Patients With Valvular Heart Disease: A Report of the American College of Cardiology/American Heart Association Task Force on Clinical Practice Guidelines." *Journal of the American College of Cardiology* vol. 70,2 (2017): 252-289.

QUESTION 4

- An 81-year-old man is evaluated before elective hip arthroplasty. Medical history is significant for hypertension and osteoarthritis.
- He reports no chest pain, palpitations, exertional dyspnea, or other symptoms of cardiovascular disease.
- His medications are lisinopril and celecoxib.

QUESTION 4

- On physical examination, vital signs are normal. The cardiopulmonary examination is normal. Range of motion of the right hip is limited by pain without overlying erythema or warmth.
- Laboratory studies reveal normal kidney function and electrolyte levels.
- A 12-lead electrocardiogram is shown. Findings are unchanged from 7 years ago.

QUESTION 4

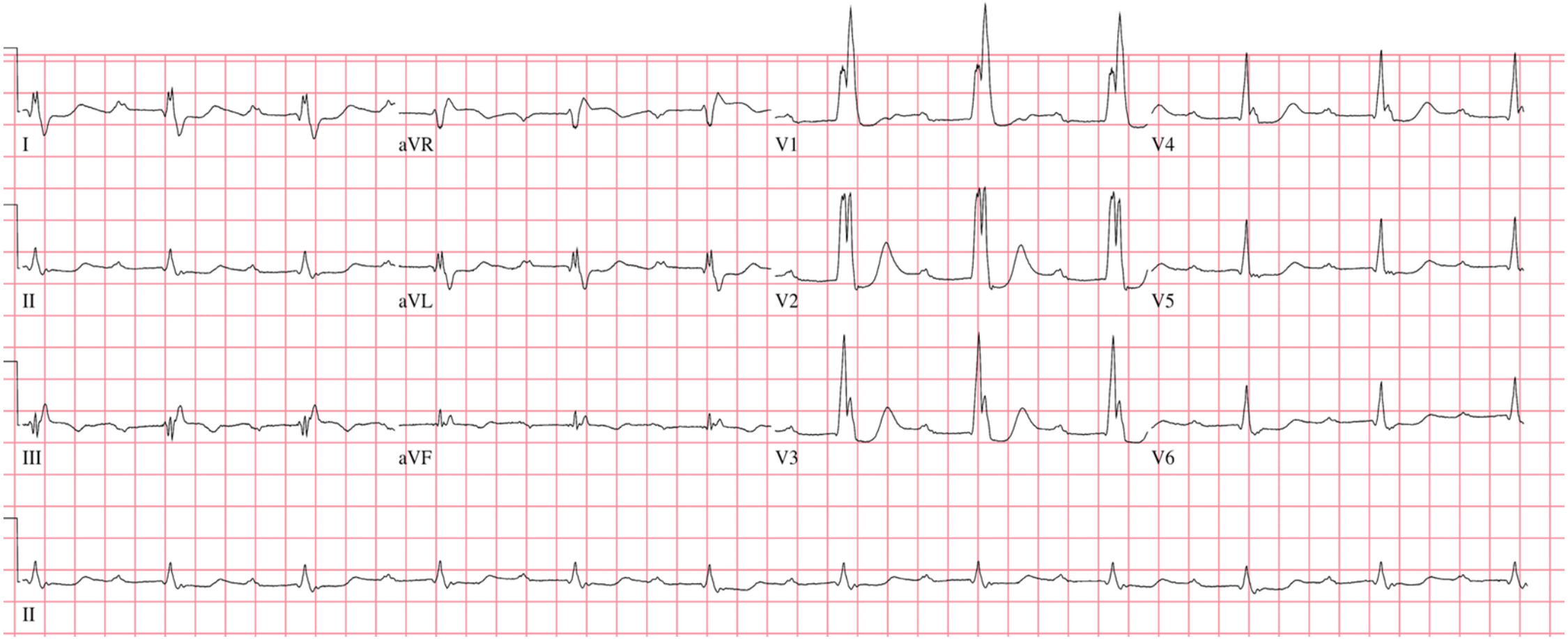

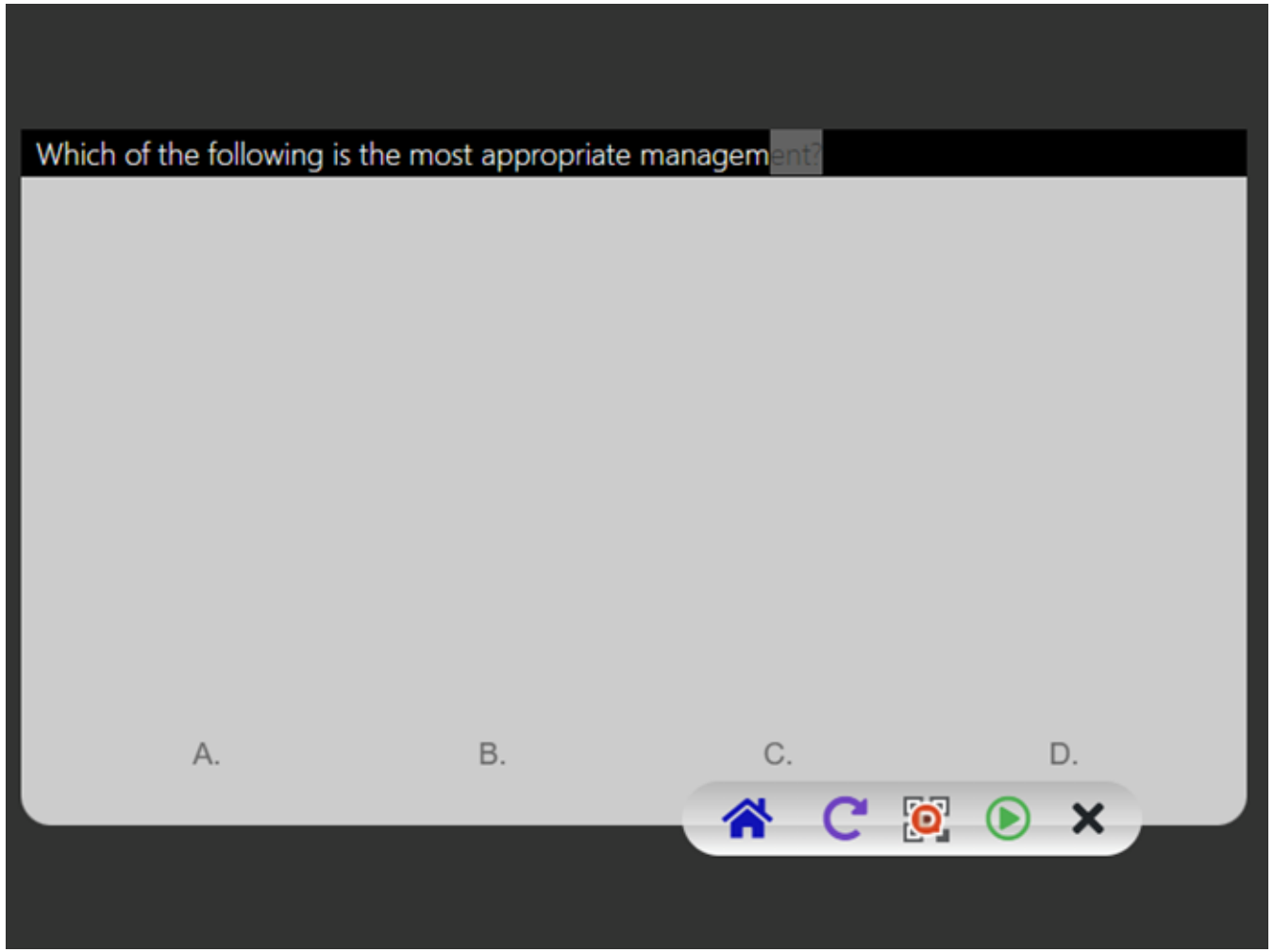

QUESTION 4

- **Which of the following is the most appropriate management?**

A. Dobutamine echocardiography
B. Echocardiography
C. Prophylactic pacemaker insertion
D. No further testing or intervention

QUESTION 4

- **Which of the following is the most appropriate management?**

A. Dobutamine echocardiography

B. Echocardiography

C. Prophylactic pacemaker insertion

D. **No further testing or intervention**

QUESTION 4

- **Educational Objective:**
  - Manage first-degree atrioventricular block accompanied by bifascicular block.

- **Key Point:**
  - Asymptomatic first-degree atrioventricular block with bifascicular block does not require pacemaker implantation.

QUESTION 5

- A 72-year-old man is evaluated for exertional left calf and foot pain. Three weeks ago, the patient developed an ulcer on the medial aspect of the left great toe.
- His medical history is significant for coronary artery disease, type 2 diabetes mellitus, hypertension, and hyperlipidemia.
- Medications are low-dose aspirin, lisinopril, metoprolol, metformin, and atorvastatin.

QUESTION 5

- On physical examination, blood pressure is 155/84 mm; other vital signs are normal.
- There are no palpable pulses in the left leg. Right femoral, popliteal, and pedal pulses are faint.

Ankle-brachial index testing:	
Right systolic brachial pressure	155 mm Hg
Left systolic brachial pressure	145 mm Hg
Left posterior tibialis pressure	255 mm Hg
Left dorsalis pedis pressure	255 mm Hg

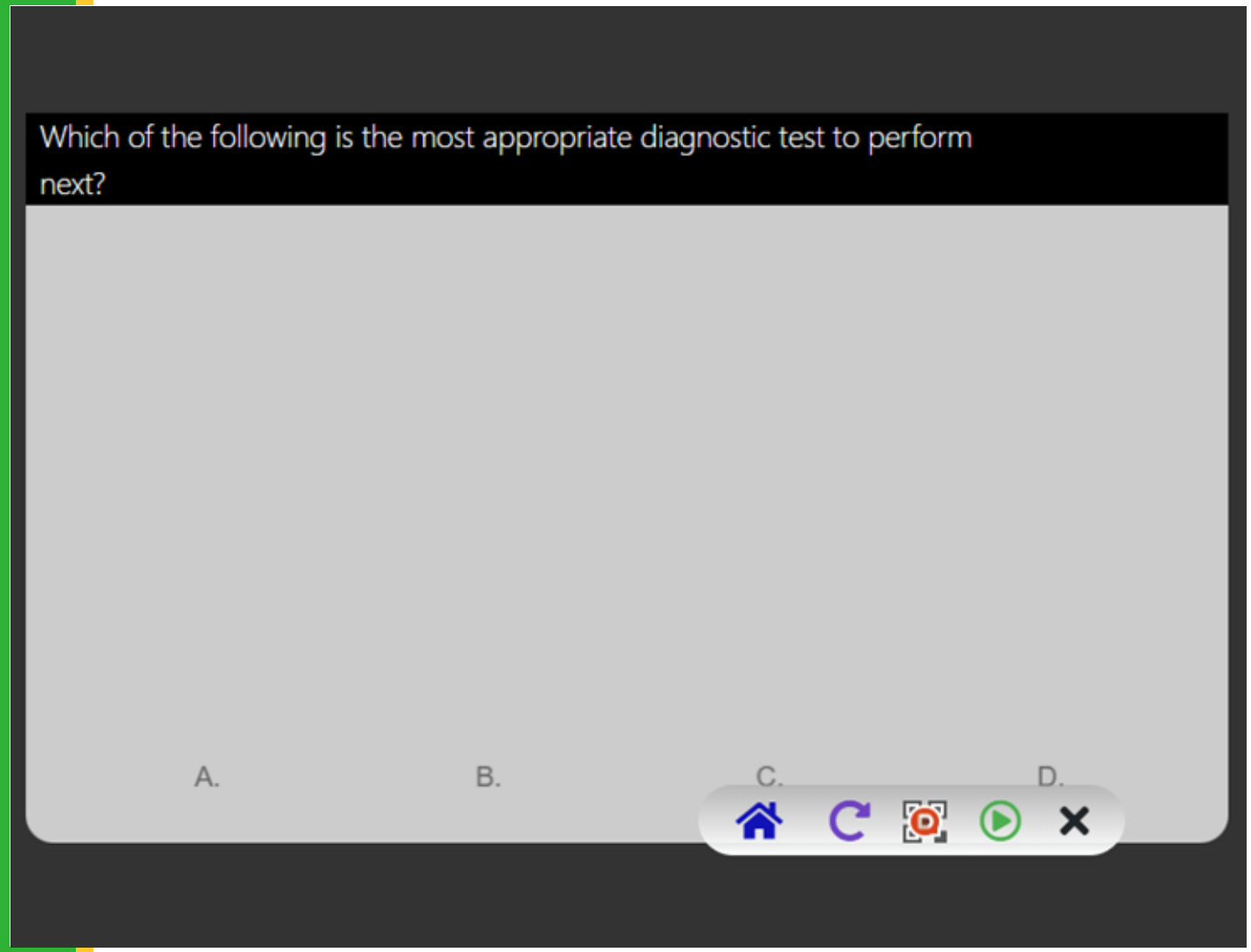

QUESTION 5

- **Which of the following is the most appropriate diagnostic test to perform next?**

A. Exercise ankle-brachial index

B. Lower extremity CT angiography

C. Toe-brachial index

D. Venous duplex ultrasonography

QUESTION 5

- **Which of the following is the most appropriate diagnostic test to perform next?**

A. Exercise ankle-brachial index

B. Lower extremity CT angiography

C. **Toe-brachial index**

D. Venous duplex ultrasonography

QUESTION 5

- **Diagnosis:**
  - Intermittent claudication, vascular ulcer
- **Which of the following is the most appropriate treatment?**

A. Exercise ankle-brachial index: if high suspicion and normal ABI

B. Lower extremity CT angiography: when planning for intervention

C. **Toe-brachial index**

D. Venous duplex ultrasonography: if suspicious for venous insufficiency/chronic DVT

QUESTION 5

- **Diagnosis:**
  - Intermittent claudication, vascular ulcer
- **Evidence**
  - Elevated ABI > 1.4 represents calcified/noncompressible vessels
  - 20-40% will **not** have occlusive peripheral artery disease

Aboyans, Victor et al. "Measurement and interpretation of the ankle-brachial index: a scientific statement from the American Heart Association." *Circulation* vol. 126,24 (2012): 2890-909.

QUESTION 5

- **Educational Objective:**
  - Diagnose peripheral artery disease in a patient with noncompressible arteries.

- **Key Point:**
  - In patients with an ankle-brachial index greater than 1.40, a toe-brachial index may be used to diagnose peripheral artery disease.

QUESTION 6

- A 16-year-old woman is evaluated for an acne breakout on her face for 6 months' duration. She has been using over-the-counter benzoyl peroxide products, but the acne is not improving.
- She is not sexually active.
- Medical history is unremarkable, and she takes no medications.

QUESTION 6

- On physical examination, vital signs are normal. Skin findings show scattered open and closed comedones on the forehead, nose, and cheeks. There are no inflammatory pustules or nodules.
- The remainder of the examination is normal.

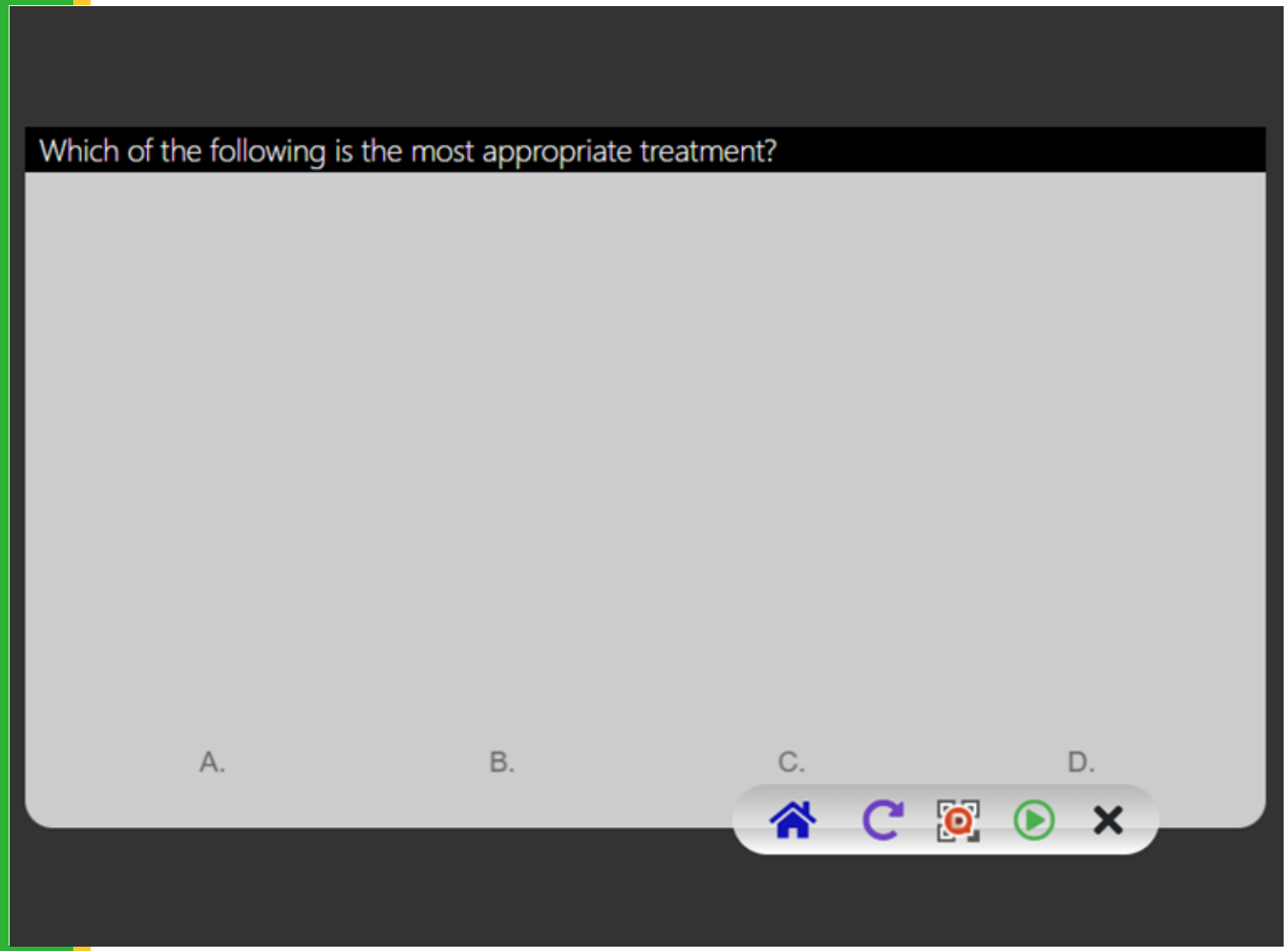

QUESTION 6

- **Which of the following is the most appropriate treatment?**

A. Isotretinoin

B. Oral contraceptive pills

C. Topical antibiotics

D. Topical retinoids

QUESTION 6

- **Which of the following is the most appropriate treatment?**

A. Isotretinoin

B. Oral contraceptive pills

C. Topical antibiotics

D. <u>Topical retinoids</u>

QUESTION 6

Acne treatment

Comedonal:

- Topical retinoids are comedolytic and normalize keratinization of hair follicle (preventive)
- Oral contraceptive pills (OCPs) less effective

Papulopustular:

- Topical retinoid + benzoyl peroxide
- Topical retinoid + antibiotic + benzoyl peroxide (reduce antibiotic resistance)

Severe or refractory or scarring:

- Systemic therapies such as isotretinoin, PO antibiotics, spironolactone, OCPs

QUESTION 6

- **Educational Objective:**
  - Treat comedonal acne.

- **Key Point:**
  - Topical retinoids are first-line treatment for comedonal acne because they are comedolytic and normalize keratinization of the hair follicle.

QUESTION 7

- A 67-year-old woman is evaluated for management of her type 2 diabetes mellitus, which was diagnosed 15 years ago. She also has diabetic nephropathy (urine albumin-creatinine ratio >300 mg/g) and retinopathy.
- She does not have hypoglycemia.
- Medications are enalapril, atorvastatin, insulin glargine, insulin aspart, and metformin.

QUESTION 7

- On physical examination, vital signs are normal. BMI is 26.
- Ophthalmoscopic examination shows non-proliferative diabetic retinopathy.
- The remainder of the physical examination is unremarkable.

QUESTION 7

- Laboratory studies show a hemoglobin A_{1c} level of 7.7% and serum creatinine level of 1.4 mg/dL (123.8 µmol/L).

- She has had a gradual decline in her estimated glomerular filtration rate (eGFR) from 50 to 39 mL/min/1.73 m^2 over the last 5 years.

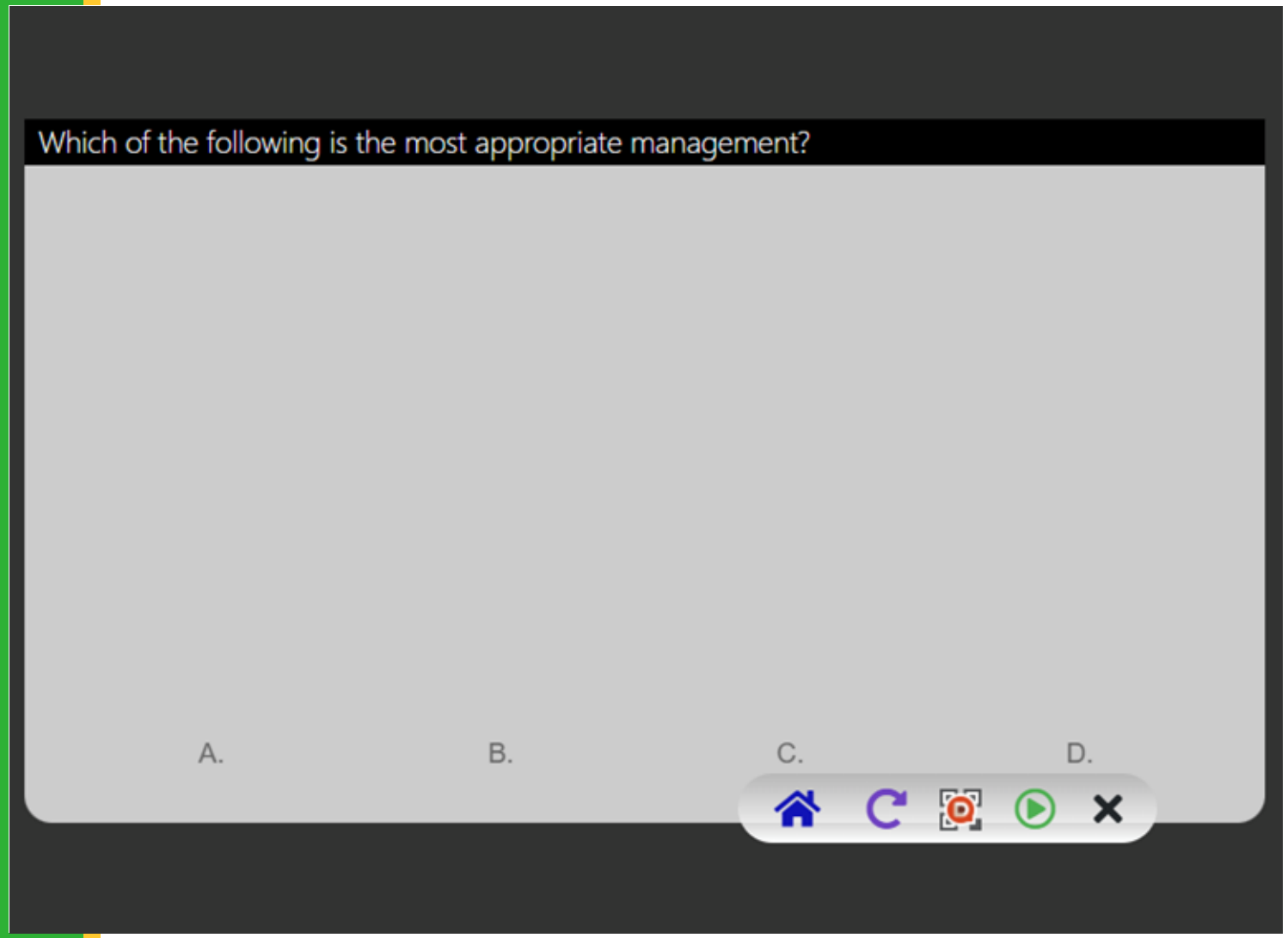

QUESTION 7

- **Which of the following is the most appropriate management?**

A. Add empagliflozin

B. Continue current regimen

C. Discontinue metformin

D. Increase insulin glargine

QUESTION 7

- **Which of the following is the most appropriate management?**

A. **Add empagliflozin**

B. Continue current regimen

C. Discontinue metformin

D. Increase insulin glargine

QUESTION 7

- **Diagnosis**
  - Type 2 diabetes mellitus with nephropathy

A. **Add empagliflozin**

B. Continue current regimen:

C. Discontinue metformin: can continue if eGFR > 30

D. Increase insulin glargine: no information on fasting BG, no significant benefit w/ stricter A1c control

QUESTION 7

- **Diagnosis**
  - Type 2 diabetes mellitus with nephropathy

- **Evidence: EMPA-REG OUTCOME**
  - **P:** Adults w/ T2DM, eGFR > 30, CVD
  - **I:** Empagliflozin 10/25mg qd
  - **C:** Placebo
  - **O:** Secondary, prespecified: worsening nephropathy (progression to microalbuminuria, doubling of serum creatinine, initiation of RRT, renal death) w/ benefit

Zinman, Bernard et al. "Empagliflozin, Cardiovascular Outcomes, and Mortality in Type 2 Diabetes." *The New England journal of medicine* vol. 373,22 (2015): 2117-28.

QUESTION 7

- **Diagnosis**

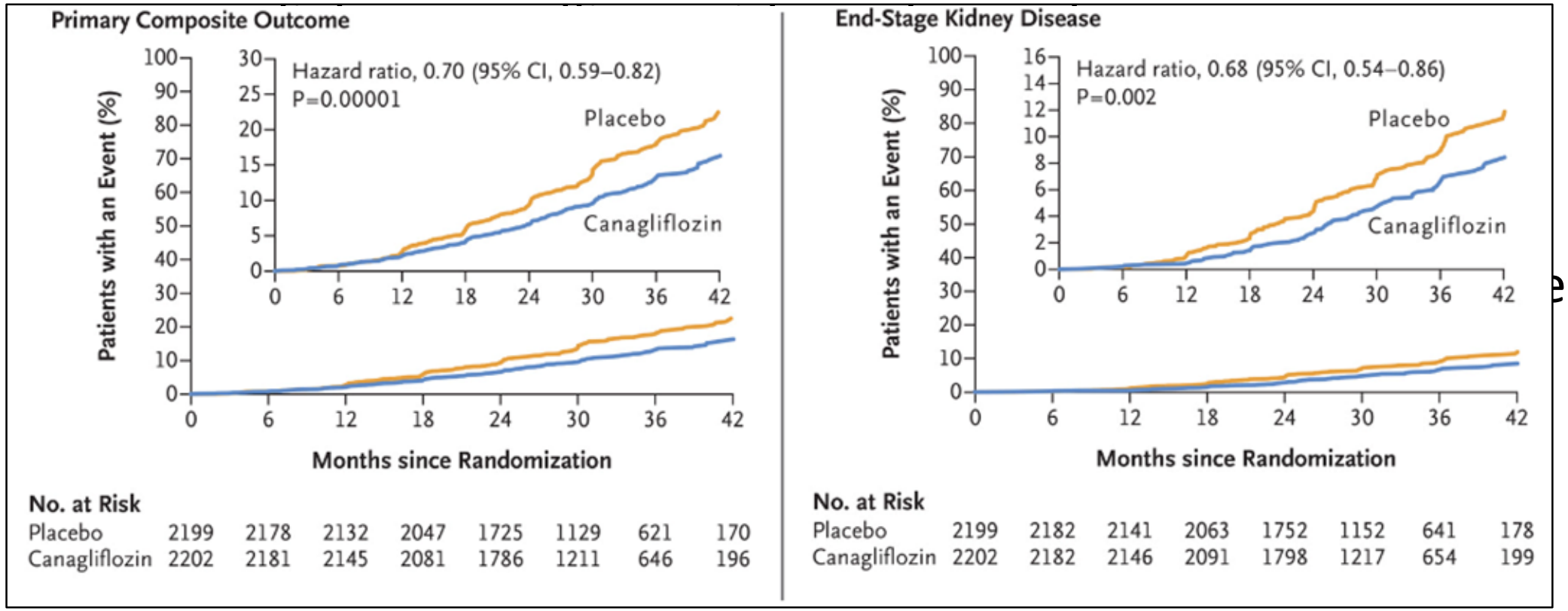

Perkovic, Vlado et al. "Canagliflozin and Renal Outcomes in Type 2 Diabetes and Nephropathy." *The New England journal of medicine* vol. 380,24 (2019): 2295-2306.

QUESTION 7

- **Educational Objective:**
  - Manage type 2 diabetes mellitus in a patient with decreasing kidney function.

- **Key Point:**
  - The use of a sodium–glucose cotransporter 2 inhibitor should be considered in patients with an estimated glomerular filtration rate greater than 30 mL/min/1.73 m^2 and urine albumin-creatinine ratio greater than 30 mg/g, particularly in those with urine albumin-creatinine ratio greater than 300 mg/g, to reduce risk for chronic kidney disease progression and cardiovascular events.

QUESTION 8

- A 65-year-old woman comes to the office to establish care.
- Her medical history is notable for hypothyroidism due to Hashimoto thyroiditis treated with levothyroxine. She does not have any symptoms at this time.
- There is no history of head or neck radiation exposure.

QUESTION 8

- On physical examination, vital signs are normal.
- The patient's thyroid gland is enlarged. The right lobe is larger than the left, and a mobile 2-cm nodule is palpable in the lower pole. There is no palpable cervical adenopathy.
- Laboratory studies show a serum thyroid-stimulating hormone level of 2.0 µU/mL (2.0 mU/L).

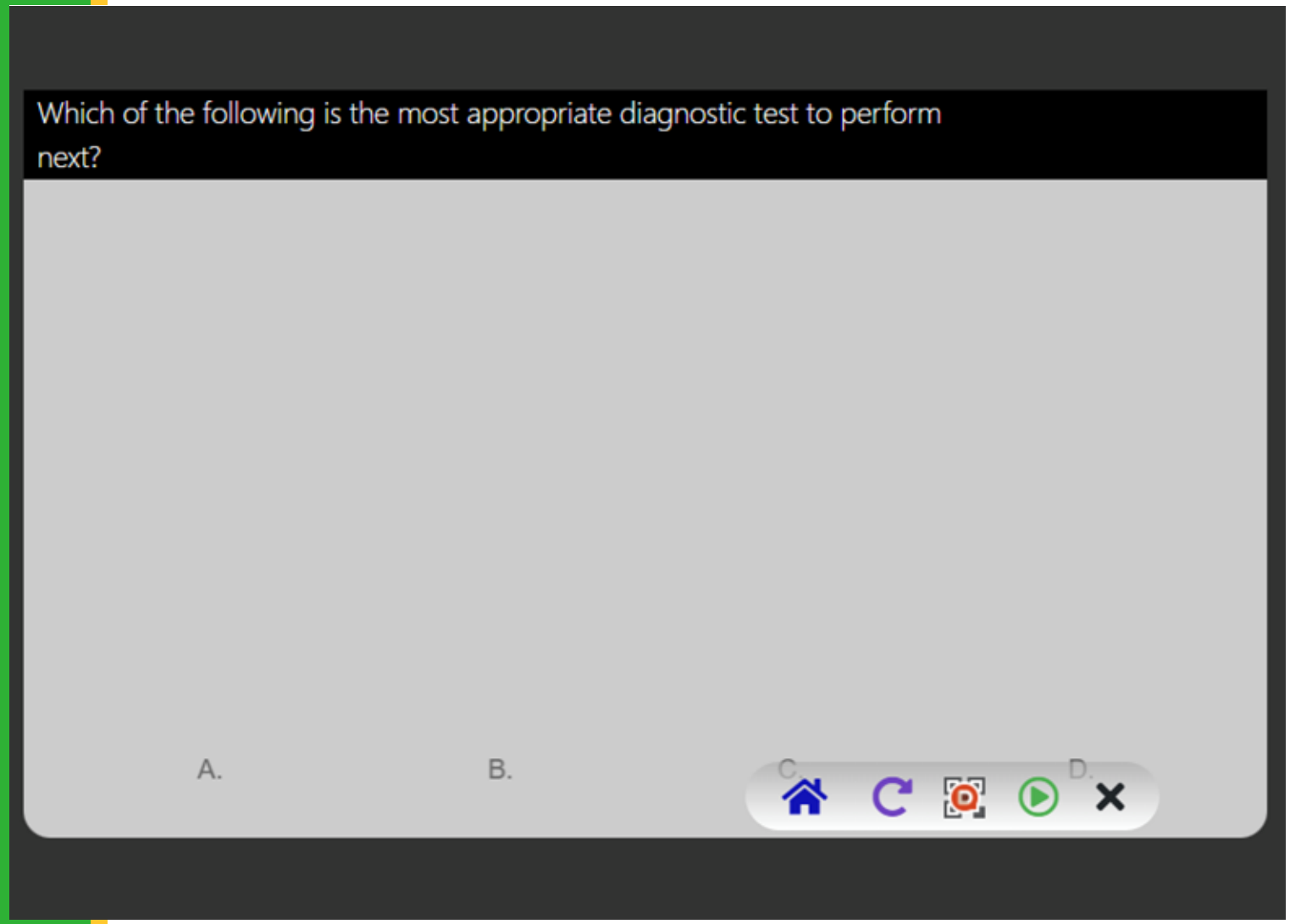

QUESTION 8

- **Which of the following is the most appropriate diagnostic test to perform next?**

A. CT scan of the neck

B. Fine-needle aspiration biopsy of the thyroid nodule

C. Thyroid uptake and ^{131}I scan

D. Ultrasound of the neck

QUESTION 8

- **Which of the following is the most appropriate diagnostic test to perform next?**

A. CT scan of the neck

B. Fine-needle aspiration biopsy of the thyroid nodule

C. Thyroid uptake and ^{131}I scan

D. **Ultrasound of the neck**

QUESTION 8

- **Which of the following is the most appropriate diagnostic test to perform next?**

Ultrasound vs CT scan

- US is superior to assess for nodules
- US is less costly
- US has less radiation

QUESTION 8

- **Which of the following is the most appropriate diagnostic test to perform next?**

Ultrasound precedes FNA

QUESTION 8

- **Which of the following is the most appropriate diagnostic test to perform next?**

Thyroid uptake and ^{131}I scan is best used to:

- evaluate for level of function of nodules ≥1 cm with low or low-normal TSH (but preferred is ^{123}I not ^{131}I)
- ^{131}I can be used for cancer in thyroid bed and/or metastatic disease

QUESTION 8

- **Educational Objective:**
  - Evaluate a thyroid nodule with neck ultrasonography.

- **Key Point:**
  - Ultrasound can confirm the presence of thyroid nodules palpated on examination and based on findings can help to determine if fine-needle aspiration is needed to assess for malignancy.

Audience Response System

Just now joining us? Join in the fun!
Take out your phone, open the camera app, hold the phone up so you can see this QR code. Click the link that appears.

OR, type in this link to your internet browser if using a computer:

https://we.dialog.live/FCM-KZZ

QUESTION 9

- A 74-year-old woman is evaluated for back pain after a fall occurring 2 weeks ago.
- Medical history is significant for deep venous thrombosis 3 years ago following a 12-hour airplane flight.

QUESTION 9

- Medications are acetaminophen as needed for back pain and calcium carbonate with vitamin D.
- On physical examination, vital signs are normal. She has minimal pain to percussion over T8.
- Her examination is otherwise normal.

QUESTION 9

Laboratory studies:	
Alkaline phosphatase	82 U/L
Calcium, serum	9.9 mg/dL (2.5 mmol/L)
Creatinine, serum	1.1 mg/dL (97.2 µmol/L)
25-Hydroxyvitamin D	40 ng/mL (99.8 nmol/L)

- Lateral spine radiograph shows 30% compression of T8, not present on prior radiographs. Bone mineral density by DEXA shows a lumbar spine T-score of −3.0 and femur neck T-score of −2.8

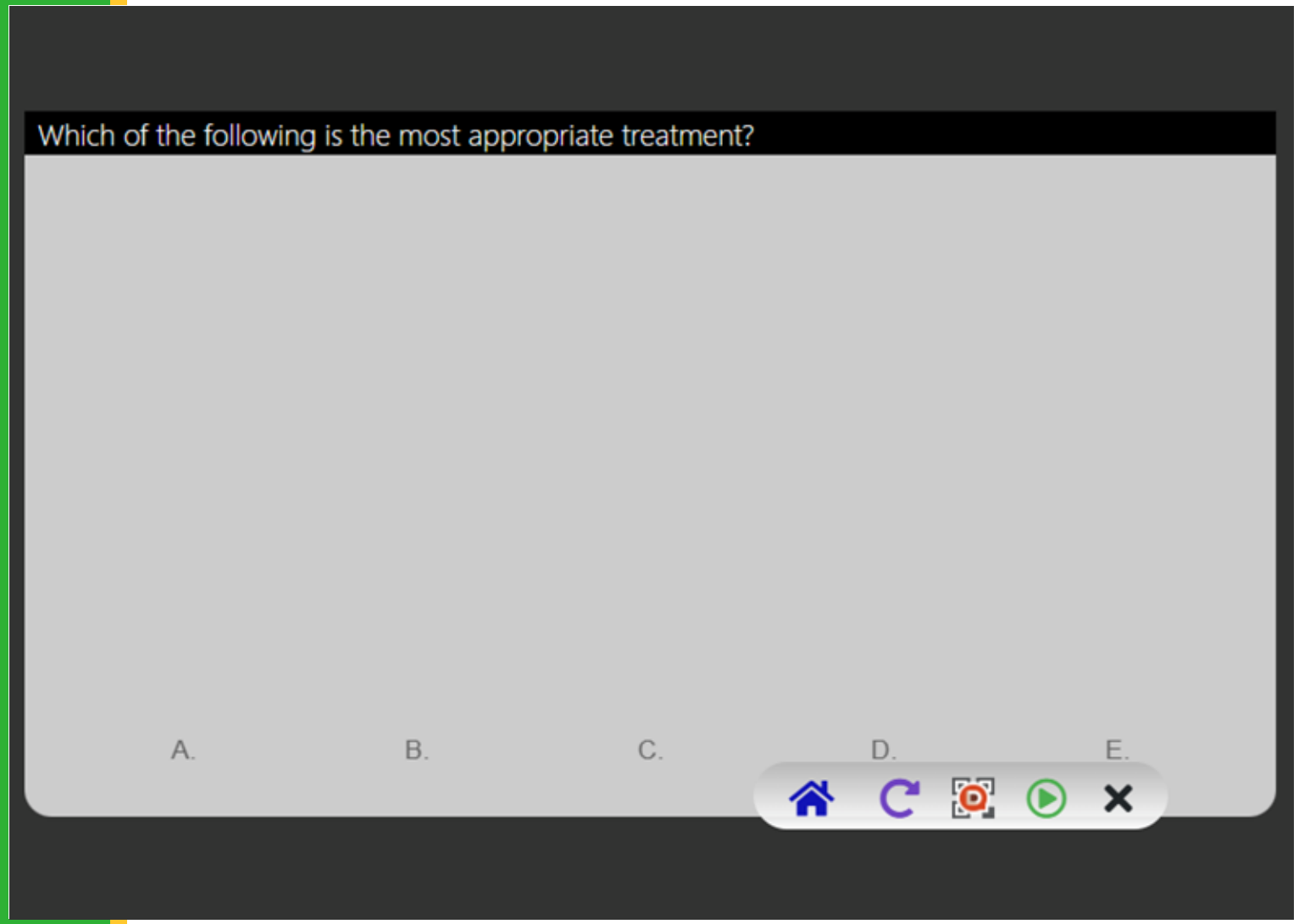

QUESTION 9

- **Which of the following is the most appropriate treatment?**

A. Alendronate

B. Calcitonin

C. Denosumab

D. Raloxifene

E. Teriparatide

QUESTION 9

- **Which of the following is the most appropriate treatment?**

A. **Alendronate**

B. Calcitonin

C. Denosumab

D. Raloxifene

E. Teriparatide

QUESTION 9

- **Diagnosis**
  - Postmenopausal osteoporosis w/ compression fracture

A. **Alendronate**

B. Calcitonin: limited efficacy in spine fractures

C. Denosumab: effective but expensive, must be continued indefinitely

D. Raloxifene: contraindicated w/ hx of VTE

E. Teriparatide: effective but expensive, preferred if severely low BMD (T-score < -3.5)

QUESTION 9

- **Diagn**
  - Pos re
- **Evide**

Table 2. Summary of Evidence on Pharmacologic Treatments for Low Bone Density and Osteoporosis

Treatment	Effect on Fracture Risk in Osteoporotic Women and Evidence Quality			Adverse Events and Evidence Quality	Fair Price for 1-Day Supply*
	Vertebral	Nonvertebral	Hip		
Bisphosphonates	Summarized individually below	Summarized individually below	Summarized individually below	As a class: atypical subtrochanteric fracture, osteonecrosis of the jaw (low-quality)	Summarized individually below
Alendronate	Improves; high-quality	Improves; high-quality	Improves; high-quality	Mild upper GI symptoms (high-quality)	Generic: $9 Brand-name (Fosamax): $130
Ibandronate	Improves; high-quality	Uncertain	Uncertain	Mild upper GI symptoms (high-quality); myalgias, cramps and limb pain	Generic: $60 Brand-name (Boniva): $588
Risedronate	Improves; high-quality	Improves; high-quality	Improves; high-quality	Mild upper GI symptoms (high-quality)	Generic: $136 Brand-name (Actonel): $337
Zoledronic acid	Improves; high-quality Improves in osteoporotic men; moderate quality	Improves; high-quality	Improves; high-quality	Mild upper GI symptoms, hypocalcaemia, influenza-like symptoms (high-quality); atrial fibrillation; arthritis and arthralgias, headaches, uveitis	Generic: $66 Brand-name (Reclast): $1105
Denosumab (injectable)	Improves; high-quality	Improves; high-quality	Improves; high-quality	Mild upper GI symptoms (high-quality), infection (moderate-quality); rash	Brand-name (Prolia): $1047
Teriparatide (injectable)	Improves; high-quality	Improves; high-quality	Unknown	Mild upper GI symptoms, headache, hypercalcemia (high-quality); hypercalciuria, renal adverse effects	Brand-name (Forteo): $2767
Raloxifene	Improves; high-quality	No effect	No effect	Hot flashes, thromboembolic events (high-quality); pulmonary embolism, cerebrovascular death	Generic: $2.40 Brand-name (Evista): $70

Qaseem A et al. Treatment of Low Bone Density or Osteoporosis to Prevent Fractures in Men and Women: A Clinical Practice Guideline Update From the American College of Physicians. Ann Intern Med. 2017 Jun 6;166(11):818-839.

QUESTION 9

- **Educational Objective:**
  - Treat postmenopausal osteoporosis.

- **Key Point:**
  - Alendronate, risedronate, zoledronic acid, and denosumab have been shown to reduce the risk for spine, hip, and nonvertebral fractures, and are generally well tolerated with low risk for serious adverse effects.

QUESTION 10

- A 65-year-old man is evaluated with upper endoscopy in follow-up for Barrett esophagus. He has had heartburn for more than 15 years, but his symptoms have been well controlled with daily omeprazole.
- He reports no weight loss or pain with swallowing and has no history of anemia.
- He stopped smoking 5 years earlier, but has a 40-pack-year history.

QUESTION 10

- Vital signs and the remainder of the physical examination are normal.
- On upper endoscopy, an area of salmon-colored mucosa is seen in the esophagus. Biopsies confirm evidence of Barrett esophagus with low-grade dysplasia.
- The pathology slides were reviewed by a second pathologist, confirming the presence of low-grade dysplasia.

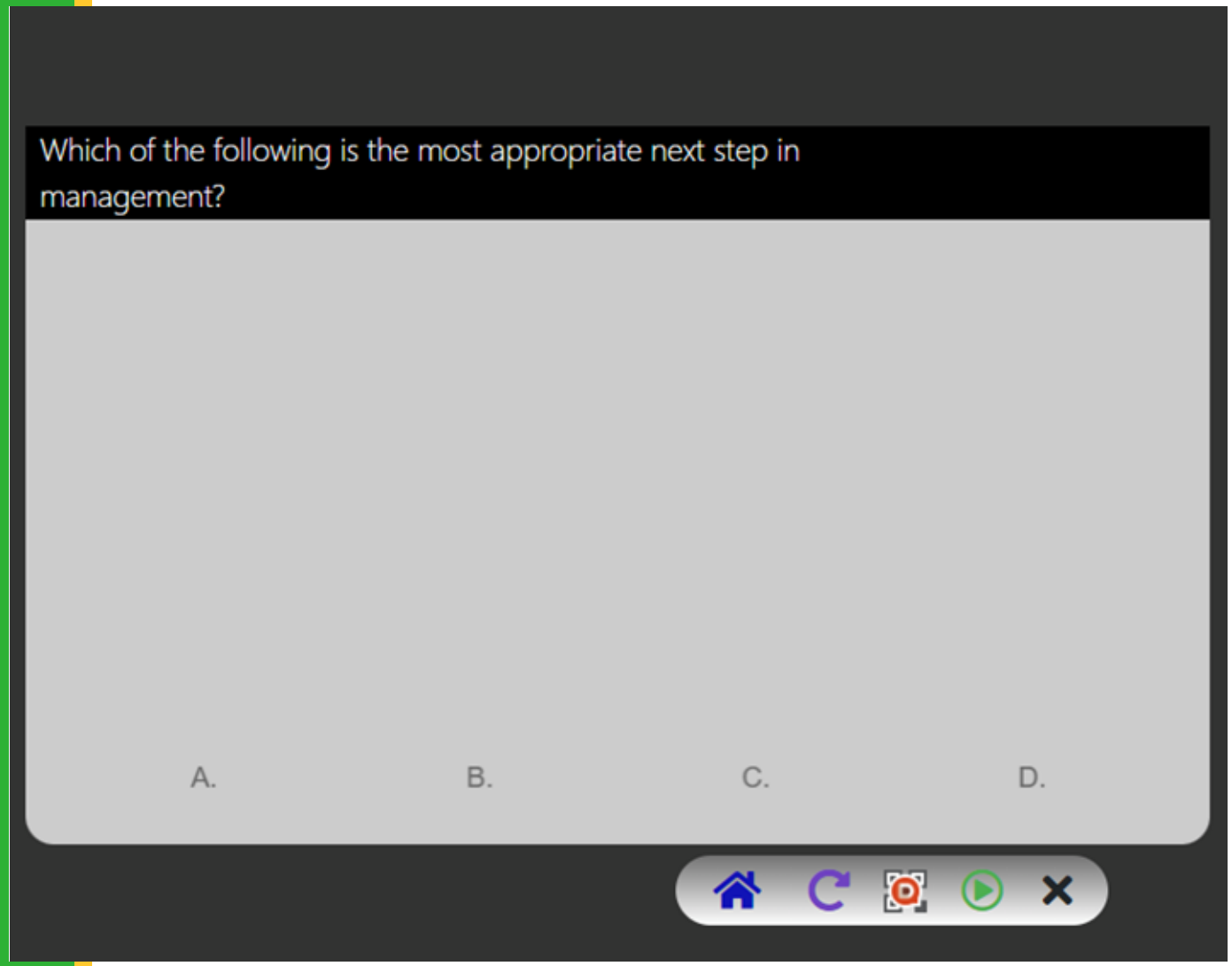

QUESTION 10

- **Which of the following is the most appropriate next step in management?**

A. Endoscopic ablation

B. Esophagectomy

C. Fundoplication

D. Repeat endoscopy in 6 months

QUESTION 10

- **Which of the following is the most appropriate next step in management?**

A. **Endoscopic ablation**

B. Esophagectomy

C. Fundoplication

D. Repeat endoscopy in 6 months

QUESTION 10

- **Which of the following is the most appropriate next step in management?**

*** different answer whether looking at ACG or AGA ***

ACG: recommends endoscopic therapy in Barrett's esophagus with low-grade dysplasia to reduce risk of progression to high-grade dysplasia or adenocarcinoma; endoscopic surveillance is an acceptable alternative

AGA: repeat EGD in 3-6 months; if low-grade dysplasia persists then therapeutic treatment and ongoing surveillance are both reasonable options

QUESTION 10

- **Which of the following is the most appropriate next step in management?**

Fundoplication: No clear evidence of superiority over medical therapy with PPI

QUESTION 10

- **Which of the following is the most appropriate next step in management?**

Esophagectomy: utilized for submucosal esophageal adenocarcinoma

QUESTION 10

- **Educational Objective:**
  - Manage a patient with Barrett esophagus with low-grade dysplasia.

- **Key Point:**
  - Barrett esophagus with low-grade dysplasia should be treated with endoscopic ablation therapy in patients without significant comorbidities.

QUESTION 11

- A 21-year-old woman is evaluated for a 6-week history of frequent bowel movements (three times daily) with intermittent passage of small amounts of blood and mucus.
- She also reports suprapubic cramping pain that is relieved with passage of stool.
- She reports no fever, chills, nausea, vomiting, or weight loss. She is otherwise healthy and takes no medication.

QUESTION 11

- On physical examination, vital signs are normal. The abdomen is scaphoid, with tenderness to palpation in the suprapubic area.
- Rectal examination is notable for a small amount of blood on the examining finger.
- Laboratory studies show a normal complete blood count and C-reactive protein level. Stool testing for enteropathogens, including *Clostridium difficile*, is negative.

QUESTION 11

- Results of colonoscopy show continuous, symmetric rectal and sigmoid inflammation characterized by erythema, edema, and friable mucosa.
- The remainder of the colonic mucosa and distal ileum is normal.
- Biopsy specimens from the rectum and sigmoid colon show evidence of mildly active chronic colitis.

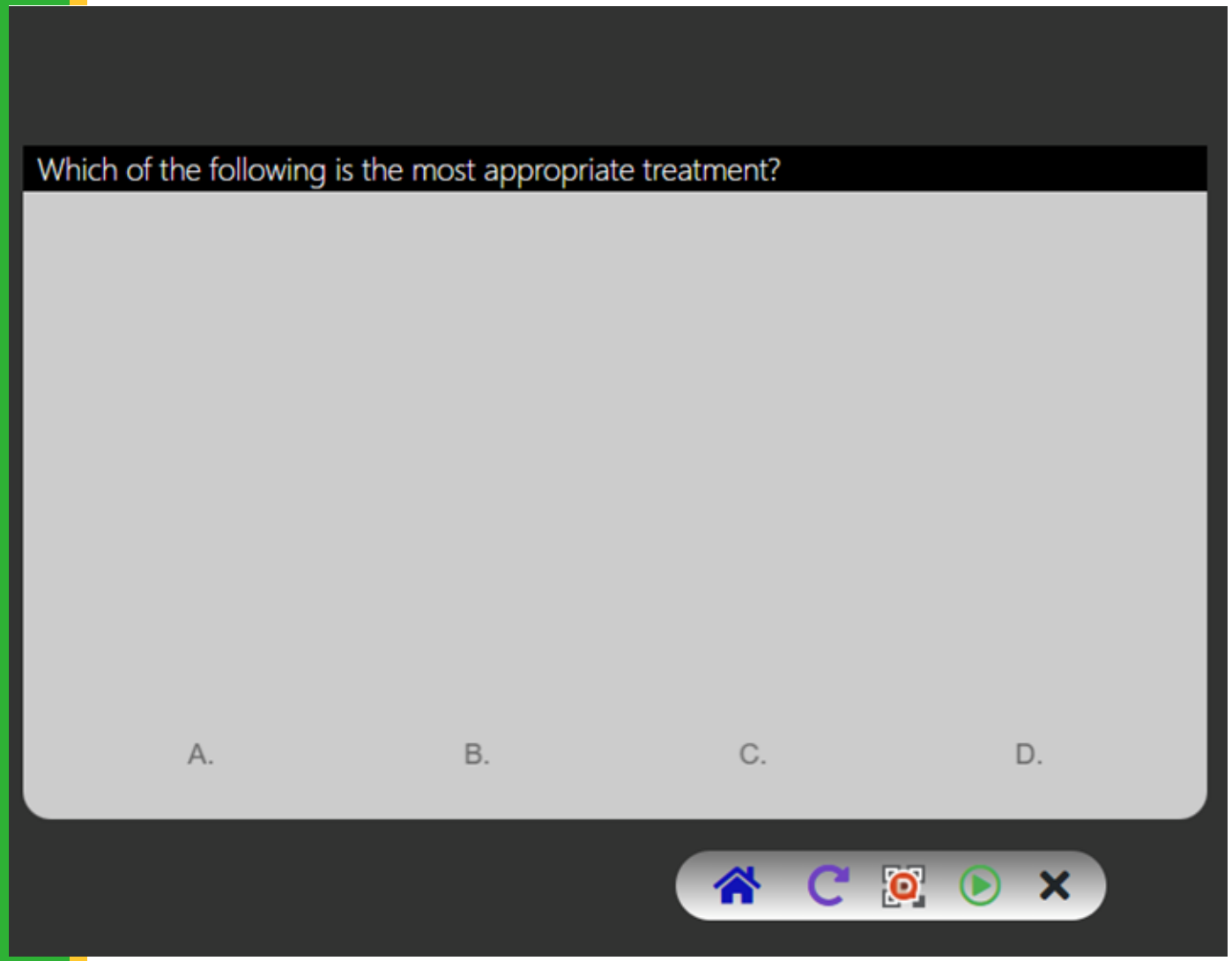

QUESTION 11

- **Which of the following is the most appropriate treatment?**

A. Mesalamine enema

B. Mesalamine suppository

C. Oral mesalamine

D. Oral mesalamine and mesalamine enema

QUESTION 11

- **Which of the following is the most appropriate treatment?**

A. Mesalamine enema

B. Mesalamine suppository

C. Oral mesalamine

D. **Oral mesalamine and mesalamine enema**

QUESTION 11

- **Diagnosis**
  - Ulcerative colitis

A. Mesalamine enema

B. Mesalamine suppository: effective for mild ulcerative proctitis

C. Oral mesalamine

D. **Oral mesalamine and mesalamine enema**

QUESTION 11

- **Diagnosis**
  - Ulcerative colitis
- **Evidence**
  - Meta erative colitis
  - Outco

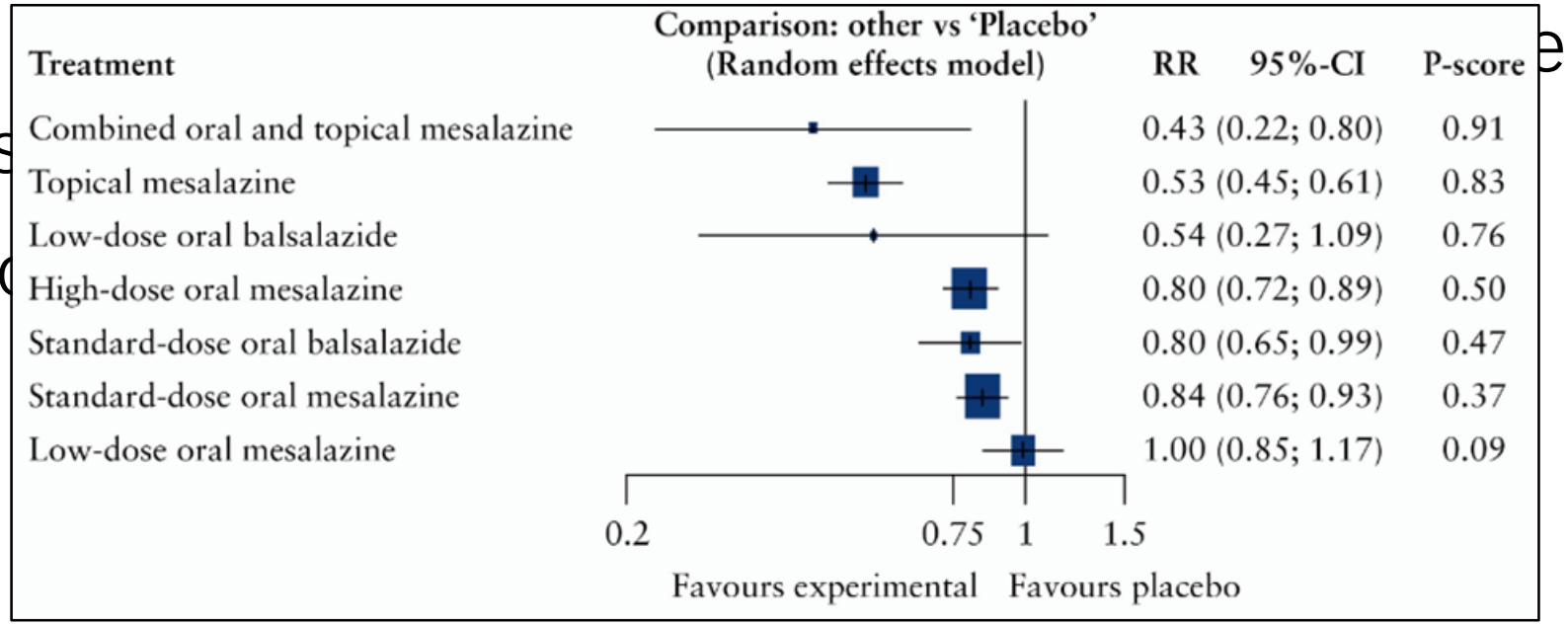

QUESTION 11

- **Educational Objective:**
  - Treat left-sided ulcerative colitis.

- **Key Point:**
  - Combined mesalamine therapy (oral and topical) is superior for induction of remission in mild to moderately active ulcerative colitis compared with oral or topical therapies alone.

QUESTION 12

- A 55-year-old man is evaluated for ascites. He recently went to the emergency department, where paracentesis was performed. He was then discharged for outpatient follow-up.
- He has a history of cirrhosis due to nonalcoholic steatohepatitis and also has hypertension.

QUESTION 12

- Endoscopy 3 months earlier showed small varices without stigmata, making prophylaxis for esophageal variceal bleeding unnecessary. His only medication is lisinopril.
- On physical examination, vital signs are normal; BMI is 28.
- Abdominal examination shows abdominal distention without tenderness.

QUESTION 12

- Laboratory studies of the ascitic fluid show a leukocyte count of 80/µL with 20% neutrophils and protein level of 1.6 g/dL (16 g/L).
- Serum studies show a creatinine level of 1.3 mg/dL (114.9 µmol/L) and sodium level of 134 mEq/L (134 mmol/L).

QUESTION 12

- An abdominal ultrasound from the emergency department shows changes consistent with cirrhosis.
- The portal vein and hepatic veins are patent with normal flow direction.
- A moderate amount of free-flowing ascites is seen.

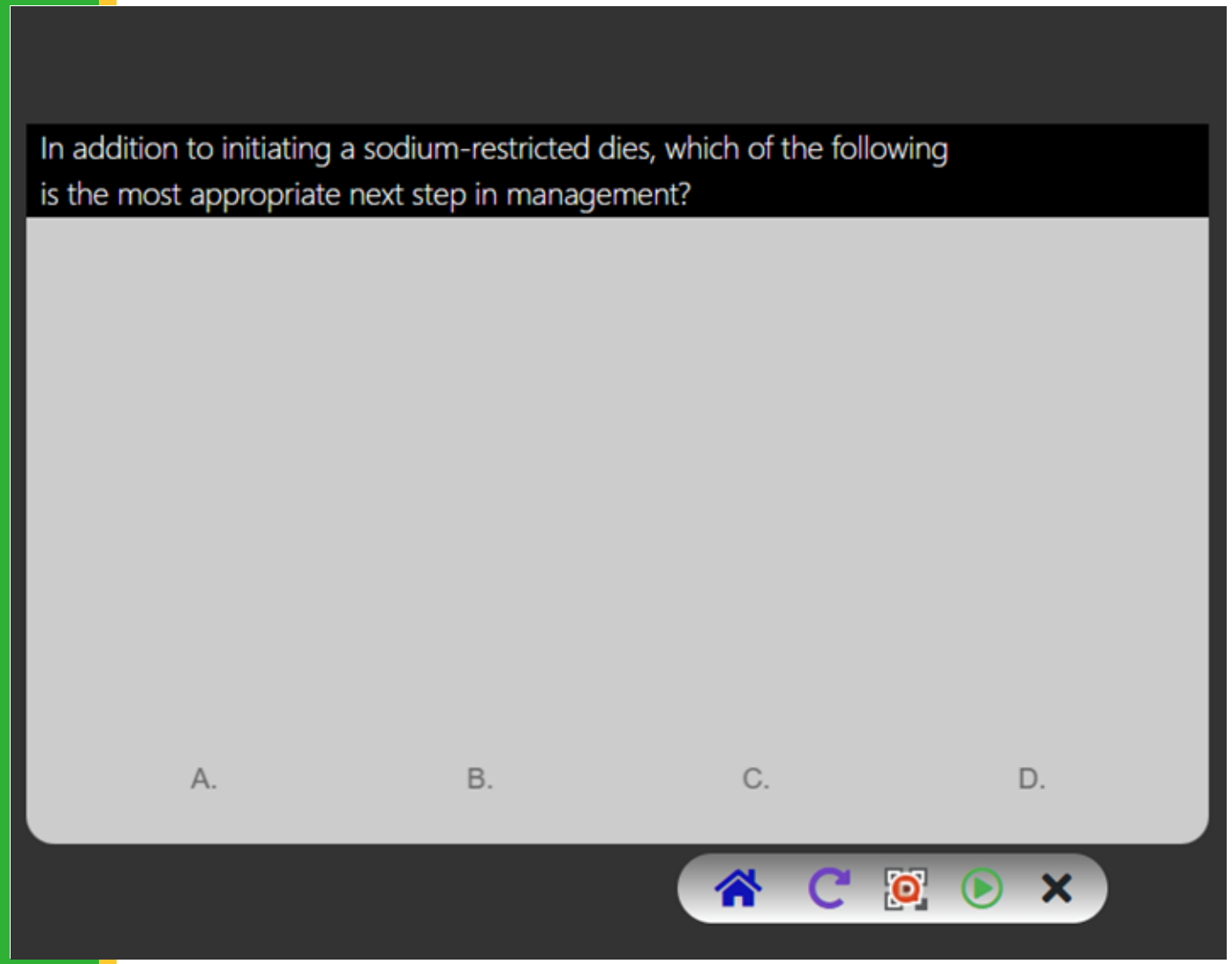

QUESTION 12

In addition to initiating a sodium-restricted dies, which of the following is the most appropriate next step in management?

A. Discontinue lisinopril
B. Initiate free-water restriction
C. Initiate propranolol
D. Insert an indwelling drain into the peritponeal cavity

QUESTION 12

- **In addition to initiating a sodium-restricted dies, which of the following is the most appropriate next step in management?**

A. **Discontinue lisinopril**

B. Initiate free-water restriction

C. Initiate propranolol

D. Insert an indwelling drain into the peritponeal cavity

QUESTION 12

- **In addition to initiating a sodium-restricted dies, which of the following is the most appropriate next step in management?**

In setting of cirrhosis avoid medications that reduce effective arterial volume or renal perfusion:

- NSAIDs
- ARBs/ACE inhibitors
- Alpha1 antagonists

QUESTION 12

- **Educational Objective:**
  - Treat ascites caused by portal hypertension.

- **Key Point:**
  - Medications that decrease kidney perfusion, including NSAIDs, ACE inhibitors, and angiotensin receptor blockers, should be discontinued in patients with ascites.

QUESTION 13

- A 49-year-old man was admitted to the ICU 3 days ago with sepsis secondary to health care–associated pneumonia. He is now being transferred to the general medical floor.
- Medical history is significant for spinal cord injury with associated lower extremity paralysis and neurogenic bladder. He is able to perform intermittent bladder catheterization.

QUESTION 13

- Medications are baclofen, enoxaparin, and levofloxacin.
- On physical examination, vital signs are normal. BMI is 19.
- Left lower lobe crackles are present on lung auscultation.
- There is flaccid paralysis of the lower extremities.
- Skin is intact without erythema over pressure points.

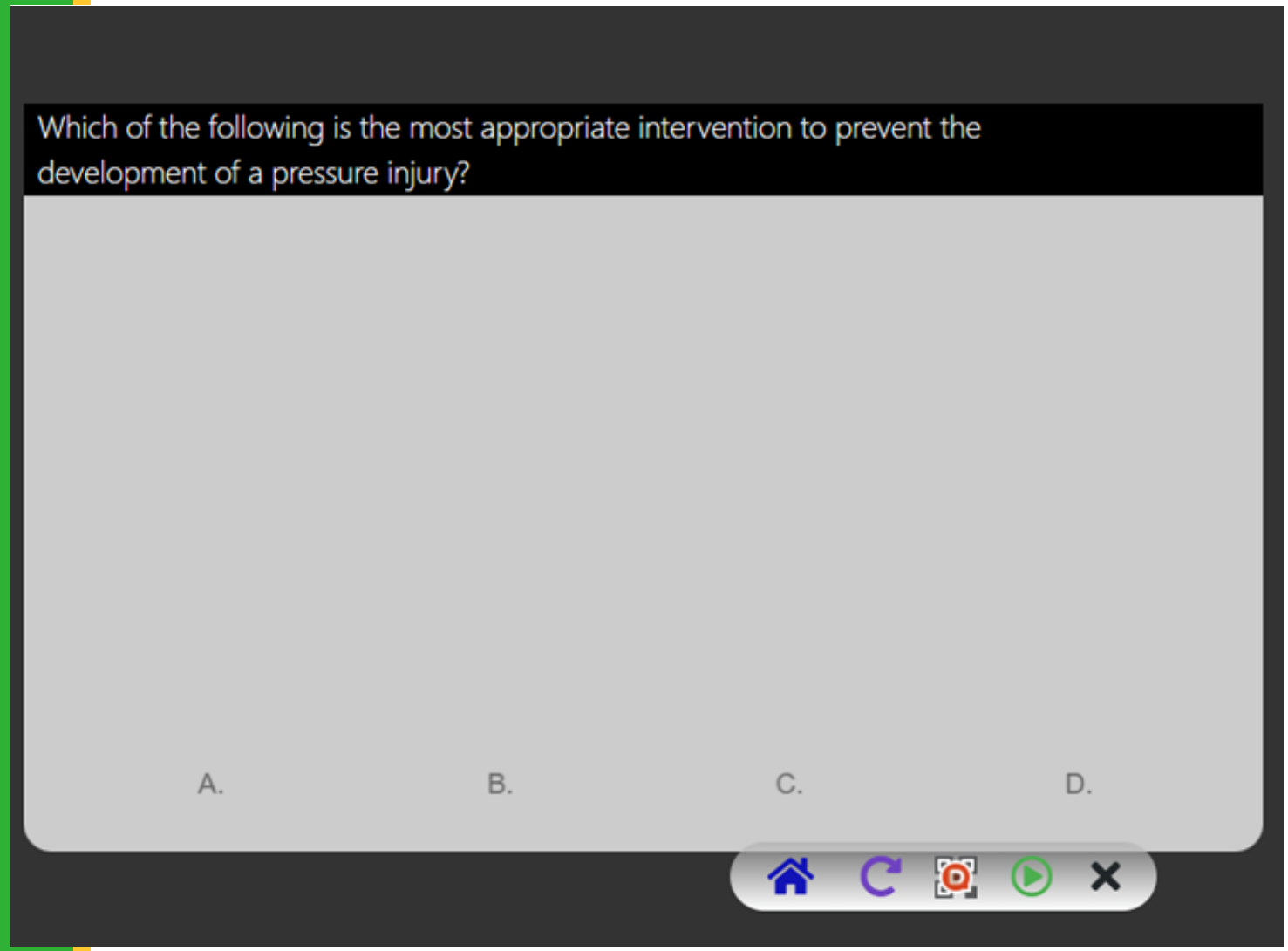

QUESTION 13

Which of the following is the most appropriate intervention to prevent the development of a pressure injury?

A. Advanced static mattress
B. Alternating air mattress
C. Frequent repositioning
D. Zinc supplementation

QUESTION 13

- **Which of the following is the most appropriate intervention to prevent the development of a pressure injury?**

A. **Advanced static mattress**

B. Alternating air mattress

C. Frequent repositioning

D. Zinc supplementation

QUESTION 13

- **Educational Objective:**
  - Prevent a pressure injury in a patient with limited mobility.

A. **Advanced static mattress**

B. Alternating air mattress: limited evidence, costly

C. Frequent repositioning: limited evidence

D. Zinc supplementation: limited evidence

QUESTION 13

- **Educational Objective:**
  - Prevent a pressure injury in a patient with limited mobility.
- **Evider**
  - Revie revention of pre
  - Adva skin, gel or foam,

Table 5. Evidence for Interventions to Reduce Incidence and Severity of Pressure Ulcers

Intervention	Quality of Evidence	Effect on Reduction in Incidence and Severity*	Data
Mattresses, overlays, or other support systems			
Static mattress or overlay vs. standard hospital mattress	Moderate	Improved	Reduced ulcer risk: RR range, 0.16 to 0.82; 1 good-quality and 4 fair-quality studies (55–59) Australian medical sheepskin overlay subgroup analysis: RRs, 0.30, 0.58, and 0.58; 2 fair-quality and 1 poor-quality studies (56, 57, 60)
Alternating-air overlay or mattress vs. standard hospital mattress	Low	Improved	Lower incidence of pressure ulcers; 3 poor-quality studies (74–76)
Nutritional supplementation vs. standard hospital diet	Low	No difference	No difference overall in pressure ulcer risk with oral or enteral supplementation (5 of 6 studies showed no difference); 1 fair-quality and 5 poor-quality studies (90–95)
Repositioning			
Repositioning intervention vs. usual care	Moderate	Mixed results	Lower risk for pressure ulcers with repositioning at a 30-degree tilt every 3 h compared with usual care (3.0% vs. 11.0%; RR, 0.27 [CI, 0.08 to 0.93]); 1 fair-quality study (96) No difference in risk for stage 2 to 4 ulcers among repositioning every 2, 3, or 4 h (2.5% vs. 0.6% vs. 3.0%, respectively [$P = 0.68$]); 1 good-quality study (97) No difference in risk for pressure ulcers among various repositioning intervals; 1 fair-quality study (98)
Small unscheduled shifts in body position vs. usual care	Low	No difference	No difference in pressure ulcer risk, but only 1 or 2 ulcers were reported in each study; 2 poor-quality studies (99, 100)

Qaseem A et al; Clinical Guidelines Committee of the American College of Physicians. Risk assessment and prevention of pressure ulcers: a clinical practice guideline from the American College of Physicians. Ann Intern Med. 2015 Mar 3;162(5):359-69.

QUESTION 13

- **Educational Objective:**
  - Prevent a pressure injury in a patient with limited mobility.

- **Key Point:**
  - An advanced static mattress or mattress overlay made of specialized sheepskin, foam, or gel provides the best protection against the development of pressure injuries in hospitalized patients.

QUESTION 14

- A 55-year-old man is evaluated in the emergency department for abrupt loss of consciousness after a fall.
- Medical history is notable for atrial fibrillation. He has otherwise been well without additional medical problems.
- Medications are warfarin and metoprolol.

QUESTION 14

- On physical examination, temperature is 37 °C (98.6 °F), blood pressure is 135/85 mm Hg, pulse rate is 83/min and irregular, and respiration rate is 16/min.
- The patient is obtunded without localizing neurologic findings. Cardiac examination reveals an irregularly irregular rhythm.
- The remainder of the examination is unremarkable.

QUESTION 14

- Head CT scan shows a large subdural hematoma.
- Laboratory studies show a hemoglobin level of 13 g/dL (130 g/L), platelet count of 183,000/µL (183×10^9/L), and INR of 3.0.
- Intravenous vitamin K is administered, and plans are made for emergent neurosurgery.

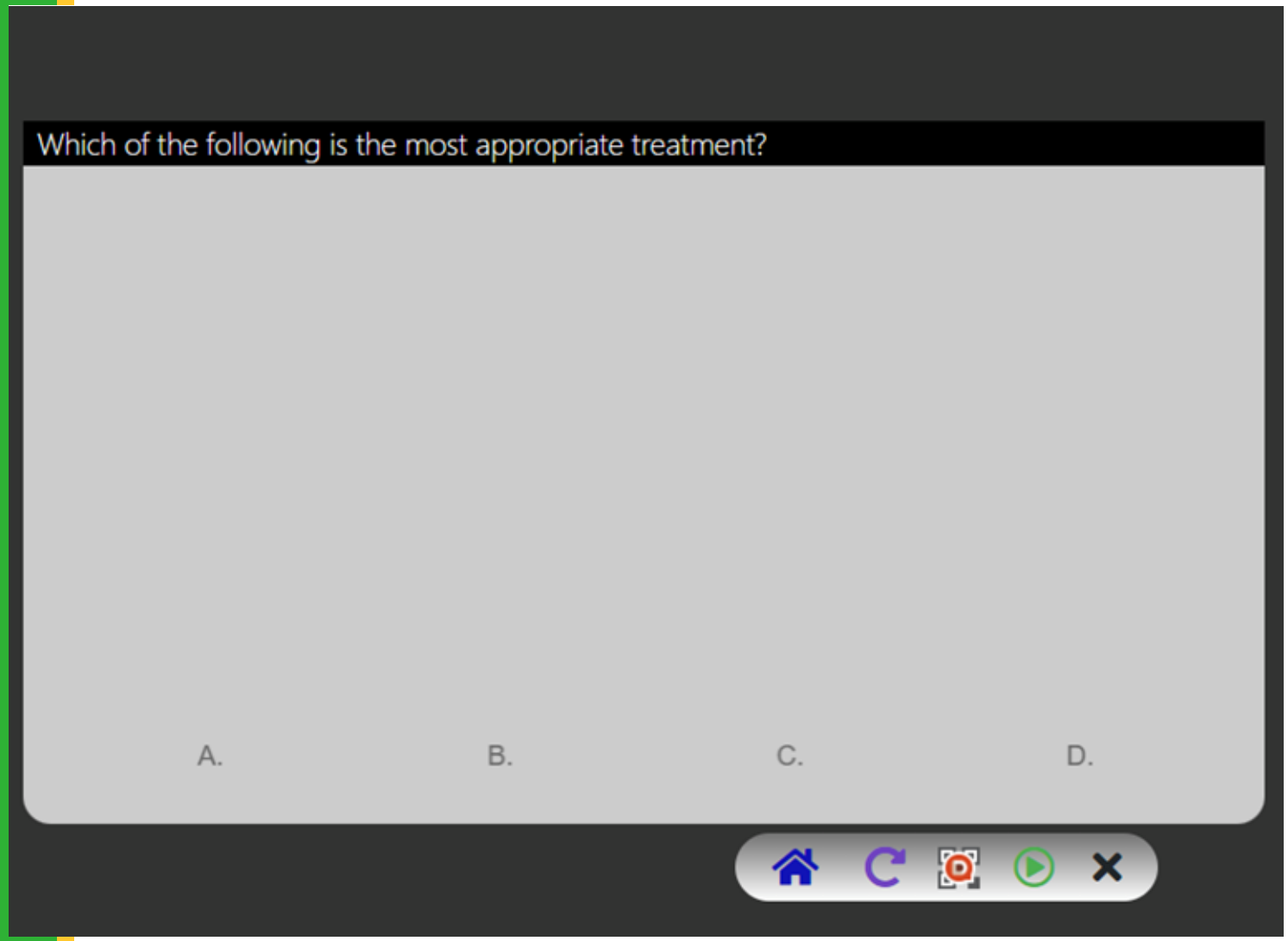

QUESTION 14

Which of the following is the most appropriate treatment?

A. Cryoprecipitate
B. Four-factor prothrombin complex concentrate
C. Fresh frozen plasma
D. Idarucizumab

QUESTION 14

- **Which of the following is the most appropriate treatment?**

A. Cryoprecipitate

B. Four-factor prothrombin complex concentrate

C. Fresh frozen plasma

D. Idarucizumab

QUESTION 14

- **Which of the following is the most appropriate treatment?**

Cryoprecipitate:

- Bleeding due to low fibrinogen
  - Disseminated intravascular coagulopathy, cardiac surgery, liver transplant, postpartum hemorrhage, trauma

QUESTION 14

- **Which of the following is the most appropriate treatment?**

Four-factor prothrombin complex concentrate:

- Bleeding due to warfarin

QUESTION 14

- **Which of the following is the most appropriate treatment?**

Fresh frozen plasma:

- Loss of multiple coagulation factors, for example liver disease or DIC

QUESTION 14

- **Which of the following is the most appropriate treatment?**

Idarucizumab:

- Bleeding due to dabigatran

QUESTION 14

- **Educational Objective:**
  - Reverse warfarin anticoagulation with four-factor prothrombin complex concentrate.

- **Key Point:**
  - Four-factor prothrombin complex concentrate should be used to reverse the effects of warfarin anticoagulation in patients experiencing severe bleeding and those requiring urgent surgery.

QUESTION 15

- A 62-year-old woman is evaluated in the emergency department for acute onset of fever and altered mental status.
- She has not been hospitalized recently or undergone any neurosurgical procedures. She takes no medication.
- On physical examination, temperature is 38.8 °C (101.9 °F), blood pressure is 149/72 mm Hg, pulse rate is 117/min, and respiration rate is 28/min.

QUESTION 15

- On neurologic examination, she is confused but awake. Passive flexion of the neck elicits resistance.
- She is photophobic, and a funduscopic examination shows no papilledema.
- The remainder of the examination is nonfocal.

QUESTION 15

- Lumbar puncture is performed, and cerebrospinal fluid evaluation shows a leukocyte count of 1625/µL (1625 × 10^6/L) with 83% neutrophils, glucose level of 40 mg/dL (2.2 mmol/L), and protein level of 505 mg/dL (5050 mg/L).
- Gram stain is pending.

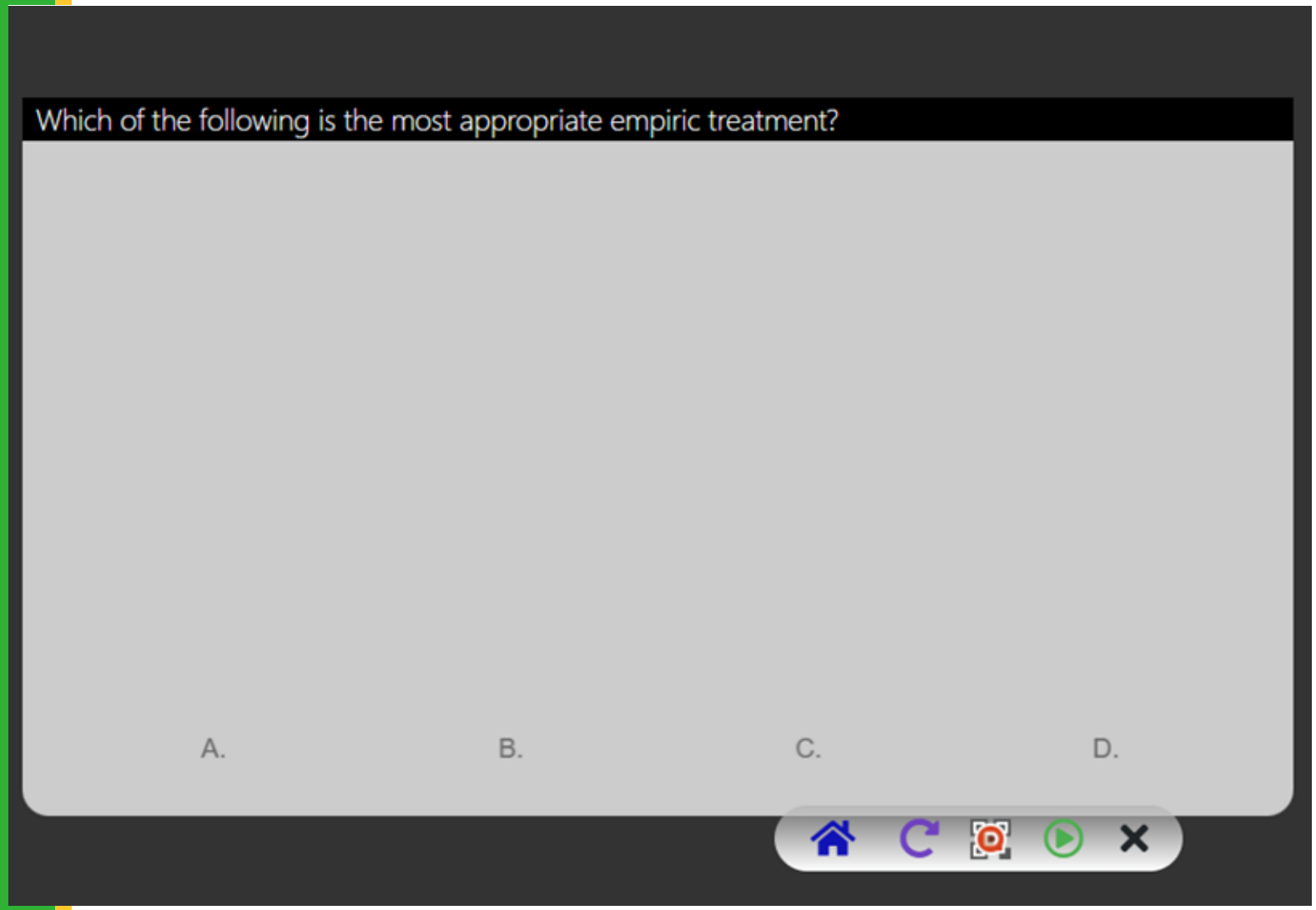

QUESTION 15

- **Which of the following is the most appropriate empiric treatment?**

A. Vancomycin plus ceftriaxone

B. Vancomycin, cefepime, and dexamethasone

C. Vancomycin, ceftriaxone, and ampicillin

D. Vancomycin, ceftriaxone, ampicillin, and dexamethasone

QUESTION 15

- **Which of the following is the most appropriate empiric treatment?**

A. Vancomycin plus ceftriaxone

B. Vancomycin, cefepime, and dexamethasone

C. Vancomycin, ceftriaxone, and ampicillin

D. Vancomycin, ceftriaxone, ampicillin, and dexamethasone

QUESTION 15

- **Diagnosis**
  - Bacterial meningitis

A. Vancomycin plus ceftriaxone: missing Listeria coverage

B. Vancomycin, cefepime, and dexamethasone: same as A

C. Vancomycin, ceftriaxone, and ampicillin

D. <u>Vancomycin, ceftriaxone, ampicillin, and dexamethasone</u>

QUESTION 15

- **Diagnosis**
  - Bacterial meningitis
- **Evider**
  - Corti

Summary of findings for the main comparison. Summary of findings table

Comparison of corticosteroids against placebo in patients with acute bacterial meningitis

Patient or population: acute bacterial meningitis
Setting: hospitals, low- and high-income countries
Intervention: corticosteroids
Comparison: placebo

Outcomes	Anticipated absolute effects* (95% CI)		Relative effect (95% CI)	No of participants (studies)	Quality of the evidence (GRADE)	Comments
	Risk with placebo	Risk with corticosteroids				
Mortality	Study population		RR 0.90 (0.80 to 1.01)	4121 (25 RCTs)	⊕⊕⊕⊖ MODERATE [1]	—
	188 per 1000	169 per 1000 (150 to 189)				
Severe hearing loss	Study population		RR 0.67 (0.51 to 0.88)	2437 (17 RCTs)	⊕⊕⊕⊕ HIGH	—
	40 per 1000	27 per 1000 (20 to 35)				
Any hearing loss	Study population		RR 0.74 (0.63 to 0.87)	2785 (20 RCTs)	⊕⊕⊕⊕ HIGH	—
	233 per 1000	173 per 1000				

Brouwer, Matthijs C et al. "Corticosteroids for acute bacterial meningitis." *The Cochrane database of systematic reviews* vol. 2015,9 CD004405. 12 Sep. 2015

QUESTION 15

- **Educational Objective:**
  - Treat suspected bacterial meningitis with empiric therapy.

- **Key Point:**
  - Adult patients with suspected bacterial meningitis should be treated empirically with ceftriaxone and vancomycin, with the addition of ampicillin in patients older than 50 years and adjunctive dexamethasone.

QUESTION 16

- A 67-year-old woman is evaluated after a diagnosis of ventilator-associated pneumonia.
- She was transferred to the ICU 3 days ago for respiratory failure secondary to Guillain-Barré syndrome and was intubated.
- Yesterday, the ventilator-associated pneumonia diagnosis was made and empiric antibiotics were started.

QUESTION 16

- Today her antibiotic therapy was de-escalated to oxacillin after her sputum culture grew methicillin-sensitive *Staphylococcus aureus*. Blood cultures were negative.
- Her medications are oxacillin and low-molecular-weight heparin; she is also undergoing plasmapheresis.

QUESTION 16

- On physical examination, temperature is 37.6 °C (99.6 °F), blood pressure and pulse rate are normal, and respiration rate is 15/min. Oxygen saturation is 97% breathing 40% FIO_2. Pulmonary examination reveals scattered rhonchi.
- A chest radiograph shows right middle and lower lobe infiltrates without effusions.

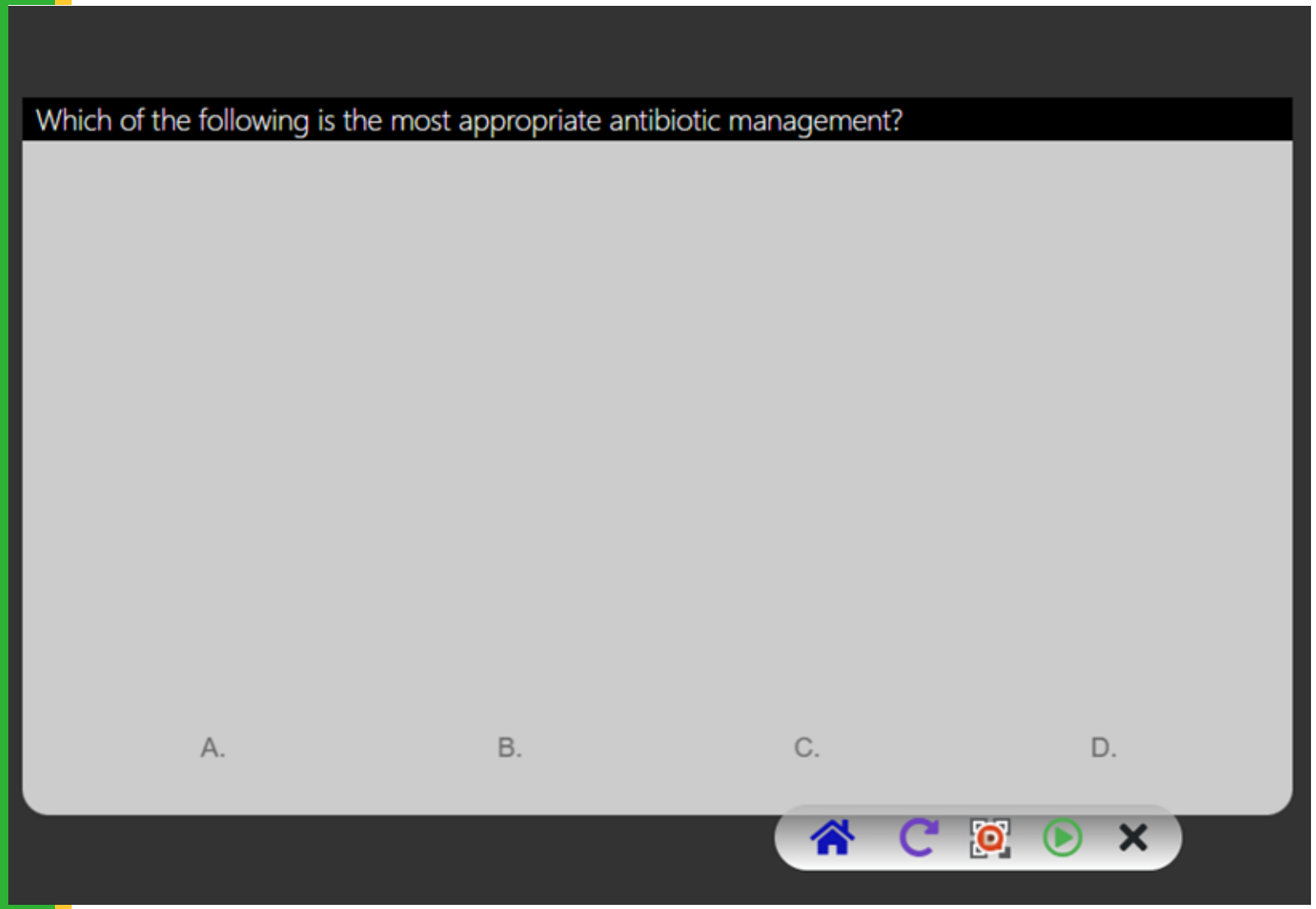

QUESTION 16

Which of the following is the most appropriate antibiotic management?

A. Continue antibiotic therapy for a total of 7 days

B. Continue antibiotic therapy for a total of 14 days

C. Continue antibiotics until extubation

D. Obtain sputum for Gram stain and culture before stopping antibiotics

QUESTION 16

- **Which of the following is the most appropriate antibiotic management?**

A. **Continue antibiotic therapy for a total of 7 days**

B. Continue antibiotic therapy for a total of 14 days

C. Continue antibiotics until extubation

D. Obtain sputum for Gram stain and culture before stopping antibiotics

QUESTION 16

- **Which of the following is the most appropriate antibiotic management?**
- IDSA recommends 7 days of antibiotics for treatment of VAP unless clinical condition does not improve as expected (for example, oxygenation, fevers)
  - No difference in mortality, recurrent pneumonia, treatment failure, length of stay, duration of ventilation as compared to 10-15 day course
  - Shorter courses do reduce risk of MDR recurrent pneumonia

QUESTION 16

- **Which of the following is the most appropriate antibiotic management?**
- Repeat sputum cultures may represent colonization and in the absence of stagnant/worsening symptoms are unlikely to represent clinical disease

QUESTION 16

- **Educational Objective:**
  - Treat ventilator-associated pneumonia for 7 days.

- **Key Point:**
  - Ventilator-associated pneumonia should be treated with a 7-day course of antibiotics; longer courses contribute to the emergence of antibiotic resistance, increase the risk for antibiotic-related adverse effects, and do not improve outcomes.

QUESTION 16

- **Which of the following is the most appropriate antibiotic management?**
- IDSA recommends 7 days of antibiotics for treatment of VAP unless clinical condition does not improve as expected (for example, oxygenation, fevers)
  - No difference in mortality, recurrent pneumonia, treatment failure, length of stay, duration of ventilation as compared to 10-15 day course
  - Shorter courses do reduce risk of MDR recurrent pneumonia

QUESTION 16

- **Which of the following is the most appropriate antibiotic management?**
- Repeat sputum cultures may represent colonization and in the absence of stagnant/worsening symptoms are unlikely to represent clinical disease

QUESTION 17

- A 65-year-old man is evaluated during a visit to establish care.
- He is interested in colorectal cancer screening; however, he adamantly refuses to undergo colon preparation, and he does not want to modify his diet for screening.
- He has never undergone colorectal cancer screening.

QUESTION 17

- Medical and family histories are unremarkable. He takes no medications.
- Physical examination, including vital signs, is normal.
- After discussing the colon preparation process and dietary restrictions with the patient and exploring his concerns, he is steadfast in his refusal.

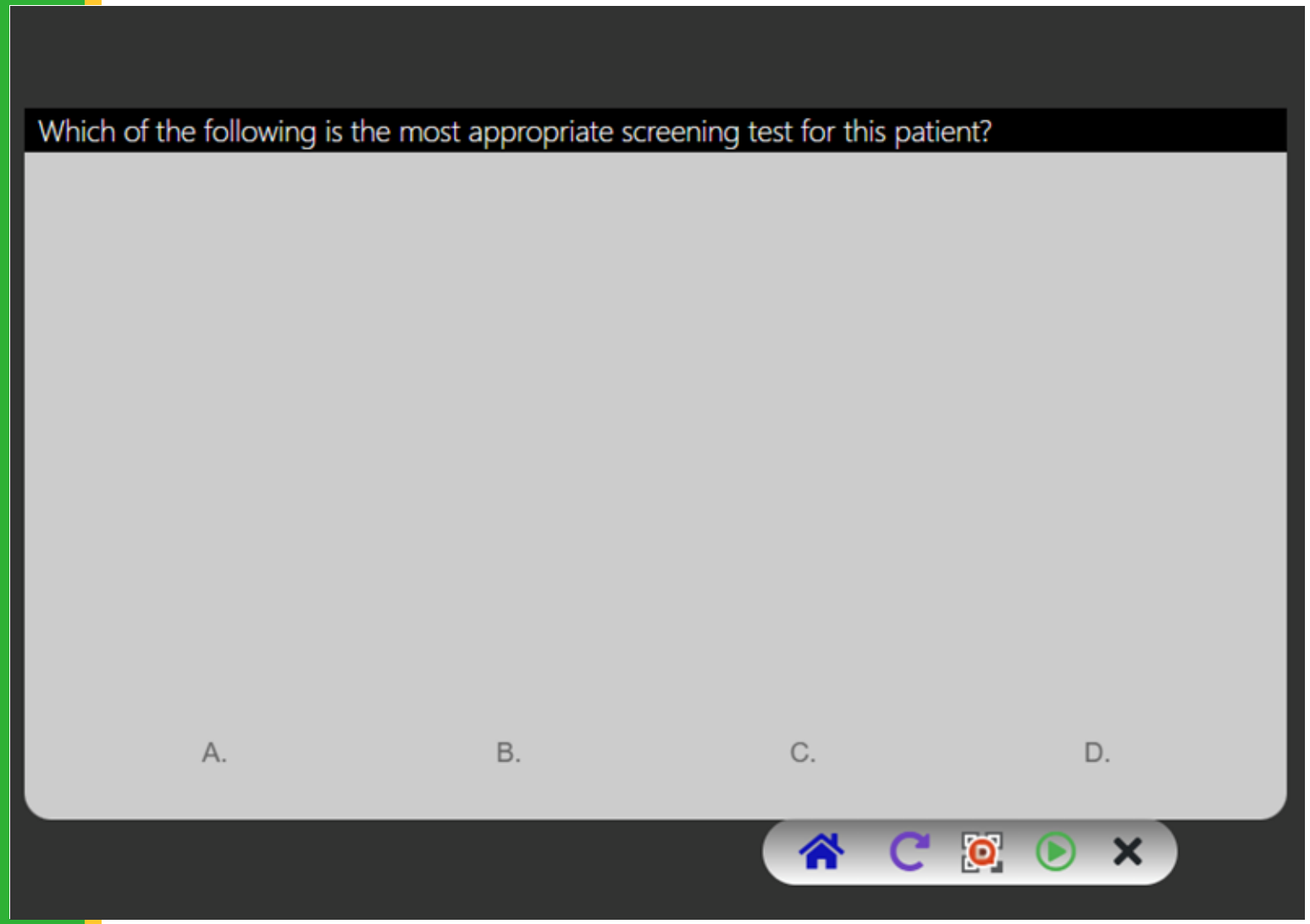

QUESTION 17

Which of the following is the most appropriate screening test for this patient?

A. Circulating methylated *SEPT9* DNA test
B. CT colonography
C. Fecal immunochemical test
D. Sensitive guaiac-based fecal occult blood test

QUESTION 17

- **Which of the following is the most appropriate screening test for this patient?**

A. Circulating methylated *SEPT9* DNA test

B. CT colonography

C. **Fecal immunochemical test**

D. Sensitive guaiac-based fecal occult blood test

QUESTION 17

- **Educational Objective:**
  - Screen for colorectal cancer in an average-risk patient with fecal immunochemical testing.

A. Circulating methylated *SEPT9* DNA test: low sensitivity

B. CT colonography: required colon prep

C. **Fecal immunochemical test**

D. Sensitive guaiac-based fecal occult blood test: requires dietary modification

QUESTION 17

- **Educati**
  - Scree
    fecal
- **Evidenc**

ent with

Table 1. Comparison of Key Features of Screening Strategies.*

Strategy and Effect on Cancer Mortality†	Quality of Evidence	Interval	Cost-Effectiveness‡	Convenience and Requirements	Detection of Precancerous Neoplasia
Guaiac FOBT and FIT: 32% lower mortality	Multiple RCTs have shown a mortality benefit (reduction in mortality) for guaiac FOBT[2-7]; although FIT is more accurate than guaiac FOBT, RCTs evaluating FIT are lacking	Annual	May be more effective and less expensive than no screening; total costs lower than no screening, because of the high expense of late-stage cancer treatment with biologic agents	Performed at home	Does not reliably detect precancerous neoplasia
Flexible sigmoidoscopy: 27% lower mortality	RCTs have shown a mortality benefit[8,9]	Every 5 yr	Cost-effective as compared with no screening and other strategies	Limited bowel preparation as compared with colonoscopy	Can detect precancerous neoplasia
Flexible sigmoidoscopy plus FIT: 38% lower mortality	A single RCT showed that flexible sigmoidoscopy plus FIT reduces cancer mortality more than sigmoidoscopy alone[10]	Annual (FIT) and every 10 yr (sigmoidoscopy)	Cost-effective as compared with no screening and other strategies	Strategy that combines endoscopic and stool testing	Can detect precancerous neoplasia
FIT-DNA: unknown effect on mortality	Data from studies showing a mortality benefit are lacking; studies were limited to the detection of cancer and precancerous polyps by FIT-DNA as compared with colonoscopy[11]	Every 1 or 3 yr	Less effective and more costly than FOBT, FIT, or colonoscopy	Performed at home	Does not reliably detect precancerous neoplasia
Colonoscopy: 68% lower mortality	A prospective cohort study showed a mortality benefit[12]	Every 10 yr	Cost-effective as compared with no screening and other strategies	Requires full bowel preparation; usually requires sedation and an escort	Can detect precancerous neoplasia
CT colonography: unknown effect on mortality	Data from studies showing a mortality benefit are lacking; studies were limited to the detection of cancer by CT colonography as compared with colonoscopy[13]	Every 5 yr	Less effective and more costly than FOBT, FIT, or colonoscopy	No sedation required but requires bowel preparation	Can detect precancerous neoplasia
Circulating methylated *SEPT9* DNA: unknown effect on mortality	Data from studies showing a mortality benefit are lacking; studies were limited to the detection of cancer by circulating methylated *SEPT9* DNA as compared with colonoscopy[14]	Unknown	Unknown	A blood test may be associated with greater adherence than that with other screening tests	Does not reliably detect precancerous neoplasia

* CT denotes computed tomography, FIT fecal immunochemical test, FIT-DNA fecal immunochemical test combined with stool DNA test, FOBT fecal occult blood test, and RCT randomized, controlled trial.
† The effect on mortality represents a comparison of the strategy with either no screening or other strategies.
‡ Cost-effectiveness was determined as the cost per quality-adjusted life-year gained.

Inadomi JM. Screening for Colorectal Neoplasia. N Engl J Med. 2017 Jan 12;376(2):149-156.

QUESTION 17

- **Educational Objective:**
  - Screen for colorectal cancer in an average-risk patient with fecal immunochemical testing.

- **Key Point:**
  - The U.S. Preventive Services Task Force recommends screening for colorectal cancer in asymptomatic adults aged 50 to 75 years; the choice of screening test should be guided by evidence, patient preferences, and local availability.

QUESTION 18

- A 60-year-old man is evaluated for a 6-month history of worsening urinary frequency, urgency, hesitancy, incomplete emptying, nocturia, and weakened stream. He reports no dysuria, incontinence, or acute urinary retention.
- Medical history is also significant for erectile dysfunction.
- He takes no medications.

QUESTION 18

- On physical examination, vital signs are normal.
- Rectal examination reveals a diffusely enlarged prostate that is nontender to palpation, with no masses or nodules noted. Testicular size is normal.
- A comprehensive metabolic profile and urinalysis are normal; an 8:00 AM total testosterone level is also normal.

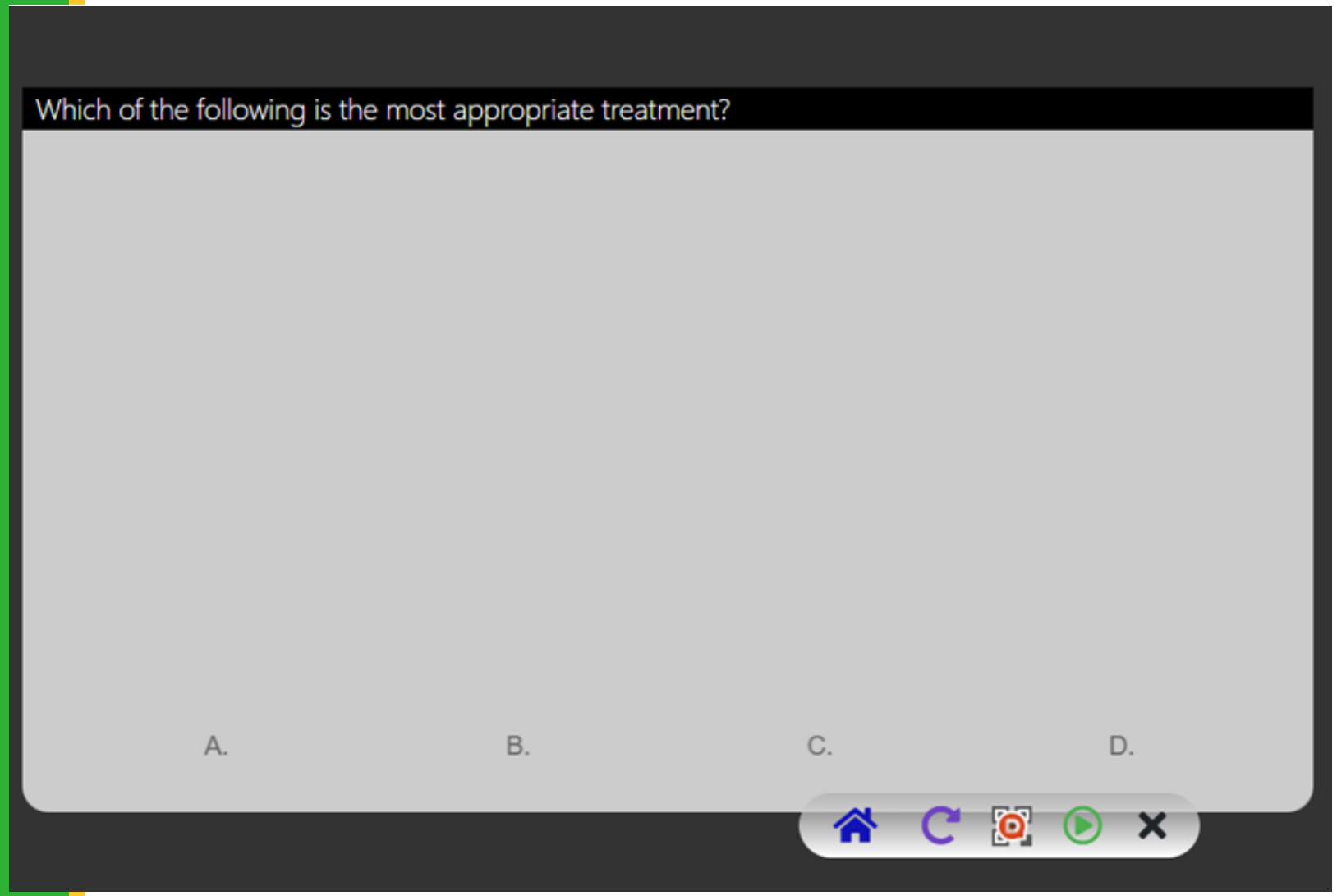

QUESTION 18

Which of the following is the most appropriate treatment?

A. Finasteride

B. Oxybutynin

C. Tadalafil

D. Tamsulosin

QUESTION 18

- **Which of the following is the most appropriate treatment?**

A. Finasteride

B. Oxybutynin

C. Tadalafil

D. Tamsulosin

QUESTION 18

- **Which of the following is the most appropriate treatment?**

Finasteride

- Can worsen erectile dysfunction
- Requires 4-6 months for efficacy for BPH
- Recommended if refractory to alpha-blocker

QUESTION 18

- **Which of the following is the most appropriate treatment?**

Oxybutynin

- Not expected to help hesitancy, weakened stream, or incomplete emptying
- Treats BPH but has only been studied after introduction of alpha-blockers

QUESTION 18

- **Which of the following is the most appropriate treatment?**

Tadalafil

- 5 mg PO q day to treat BPH or ED
- (not the 10-20 mg q 24-36 hour PRN dosing for ED, or 2.5 mg PO q day dose for ED)

QUESTION 18

- **Which of the following is the most appropriate treatment?**

Tamsulosin

- Treats BPH within days but does not treat ED

QUESTION 18

- **Which of the following is the most appropriate treatment?**

Oxybutynin

- Not expected to help hesitancy, weakened stream, or incomplete emptying
- Treats BPH but has only been studied after introduction of alpha-blockers

QUESTION 18

- **Which of the following is the most appropriate treatment?**

Tadalafil

- 5 mg PO q day to treat BPH or ED
- (not the 10-20 mg q 24-36 hour PRN dosing for ED, or 2.5 mg PO q day dose for ED)

QUESTION 18

- **Which of the following is the most appropriate treatment?**

Tamsulosin

- Treats BPH within days but does not treat ED

QUESTION 18

- **Educational Objective:**
  - Treat benign prostatic hyperplasia and erectile dysfunction with tadalafil.

- **Key Point:**
  - For patients with concomitant benign prostatic hyperplasia and erectile dysfunction, a trial of tadalafil (a phosphodiesterase-5 inhibitor) has been shown to be effective and is the only FDA-approved option to treat both conditions.

QUESTION 19

- An 18-year-old woman is brought to the emergency department by friends.
- She is confused and febrile. Her friends state that she took 3,4-methylenedioxymethamphetamine (ecstasy) at a party and was previously well.
- There is no other medical history.

QUESTION 19

- On physical examination, the patient is confused and oriented to her name only.
- Temperature is 38.9 °C (102.0 °F), blood pressure is 148/94 mm Hg, pulse rate is 108/min, respiration rate is 20/min, and oxygen saturation is 96% breathing 2 L/min oxygen by nasal cannula.
- The remainder of the examination is unremarkable.

QUESTION 19

Laboratory studies:	
Blood urea nitrogen	11 mg/dL (3.9 mmol/L)
Creatinine	0.8 mg/dL (70.7 µmol/L)
Electrolytes	
Sodium	118 mEq/L (118 mmol/L)
Potassium	3.5 mEq/L (3.5 mmol/L)
Chloride	88 mEq/L (88 mmol/L)
Bicarbonate	21 mEq/L (21 mmol/L)
Glucose	88 mg/dL (4.9 mmol/L)
Urine osmolality	405 mOsm/kg H_2O

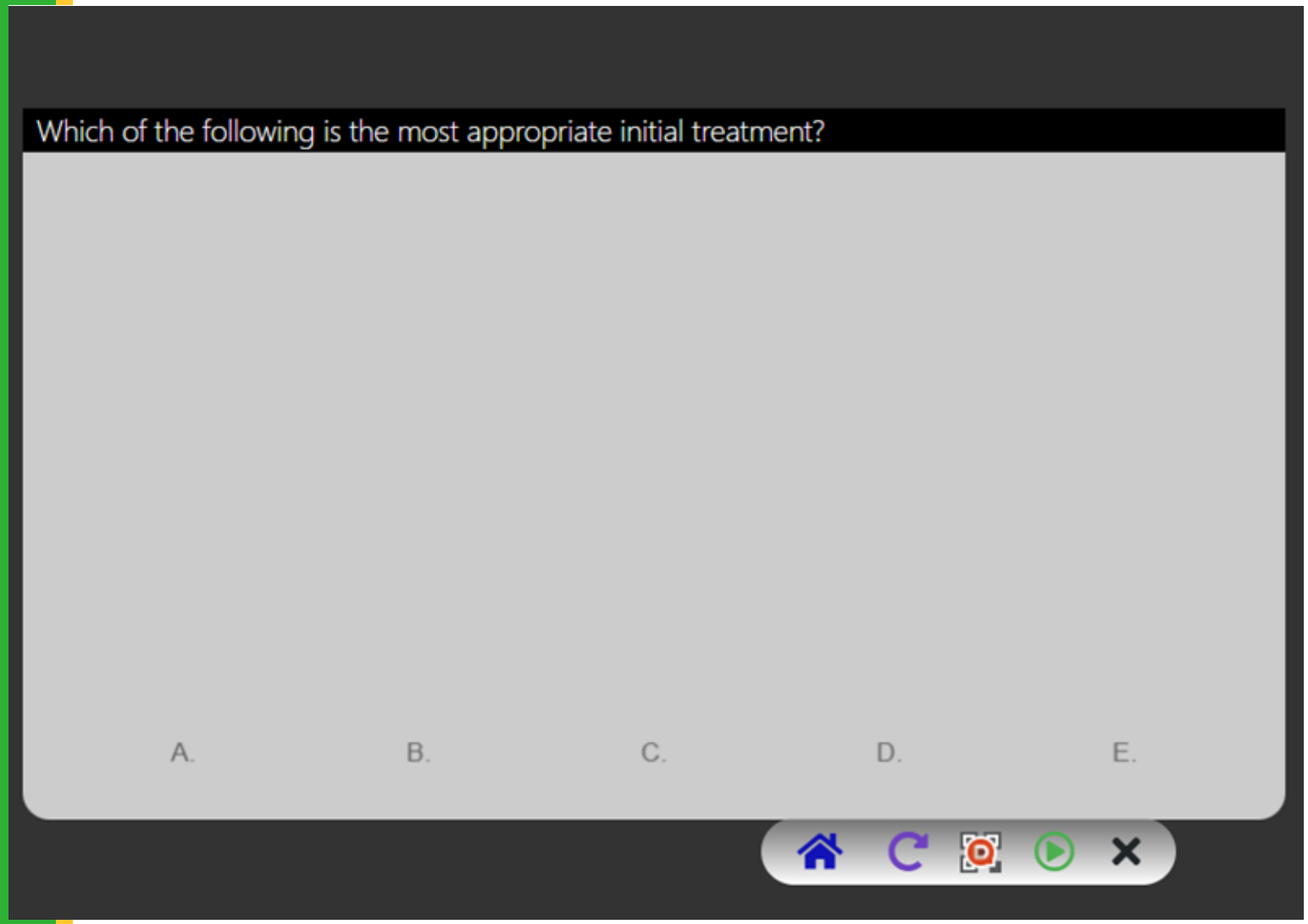

QUESTION 19

Which of the following is the most appropriate initial treatment?

A. 0.9% sodium chloride, 100 mL/h

B. 100-ml bolus of 3% saline

C. Fluid restriction

D. Oral urea

E. Tolvaptan

QUESTION 19

- **Which of the following is the most appropriate initial treatment?**

A. 0.9% sodium chloride, 100 mL/h

B. **100-ml bolus of 3% saline**

C. Fluid restriction

D. Oral urea

E. Tolvaptan

QUESTION 19

- **Diagnosis**
  - Symptomatic acute hyponatremia

A. 0.9% sodium chloride, 100 mL/h: could worsen Na in SIADH

B. **100-ml bolus of 3% saline**

C. Fluid restriction: inappropriate if symptomatic

D. Oral urea: for chronic hyponatremia

E. Tolvaptan: will not result rapid correction

QUESTION 19

- **Educational Objective:**
  - Treat acute hyponatremia in a symptomatic patient with hypertonic saline.

- **Key Point:**
  - Treatment of acute symptomatic hyponatremia includes a 100-mL bolus of 3% saline to increase the serum sodium level by 2 to 3 mEq/L (2-3 mmol/L).

QUESTION 20

- A 75-year-old man is hospitalized for treatment of extreme agitation and delirium after developing a urinary tract infection (UTI).
- He has a 1-year history of dementia with Lewy bodies.
- According to his wife, the patient has nighttime visual hallucinations 4 or 5 times per week but is rarely bothered by them.

QUESTION 20

- Home medications are simvastatin and aspirin.
- On physical examination, blood pressure is 150/92 mm Hg and pulse rate is 98/min; other vital signs are normal.
- The patient is agitated and disoriented and appears to be having visual hallucinations. Although his agitation steadily increases, he does not become aggressive.

QUESTION 20

- His UTI is being treated appropriately. No other clear sources of the delirium are present.
- Environmental interventions are instituted to help abate his symptoms.

Which of the following medications is most likely to be effective in treating his acute agitation?

A.

B.

C.

D.

QUESTION 20

Which of the following medications is most likely to be effective in treating his acute agitation?

A. Alprazolam
B. Diphenhydramine
C. Donepezil
D. Haloperidol

QUESTION 20

- **Which of the following medications is most likely to be effective in treating his acute agitation?**

A. Alprazolam

B. Diphenhydramine

C. **Donepezil**

D. Haloperidol

QUESTION 20

- **Which of the following medications is most likely to be effective in treating his acute agitation?**

Alprazolam

QUESTION 20

- **Which of the following medications is most likely to be effective in treating his acute agitation?**

Diphenhydramine

QUESTION 20

- **Which of the following medications is most likely to be effective in treating his acute agitation?**

Donepezil

Table 2. Outcome measures

	Donepezil ($n = 19$)	Placebo ($n = 14$)
Delirium, N (%)	2 (9.5)	5 (35.7)
Length of hospital stay (days)		
Mean (SE)	9.9 (0.73)	12.1 (1.09)
Range	7–20	7–20

QUESTION 20

- **Which of the following medications is most likely to be effective in treating his acute agitation?**

Haloperidol

Odd ratios of transition to a higher level of care post-hospitalization (n = 178).

Variable	Odds Ratio[a] (95% CI)
Inpatient antipsychotic use other than quetiapine, clozapine (versus use of quetiapine, clozapine, or no antipsychotic use)	2.41 (1.06, 5.47)

QUESTION 20

- **Educational Objective:**
  - Treat a patient who has dementia with Lewy bodies and acute agitation with donepezil.

- **Key Point:**
  - Haloperidol is absolutely contraindicated in dementia with Lewy bodies; donepezil is a safer alternative and may improve the behavioral and cognitive symptoms associated with dementia.

QUESTION 21

- A 24-year-old woman is evaluated for a breast lump. She has had no breast trauma or discharge from the nipples.
- She is nulliparous and has regular menstrual cycles. Medical history is otherwise unremarkable.
- The patient's mother was recently diagnosed with breast cancer at age 58 years; no other family members have breast or ovarian cancer.

QUESTION 21

- Her only medication is an oral contraceptive pill.
- On physical examination, vital signs are normal. BMI is 25.
- A breast examination reveals no skin changes, with dense breast tissue bilaterally.
- She has a firm, 2-cm, nontender, mobile mass with well-defined margins in the upper outer quadrant of the left breast. There is no evidence of axillary, cervical, or supraclavicular lymphadenopathy.

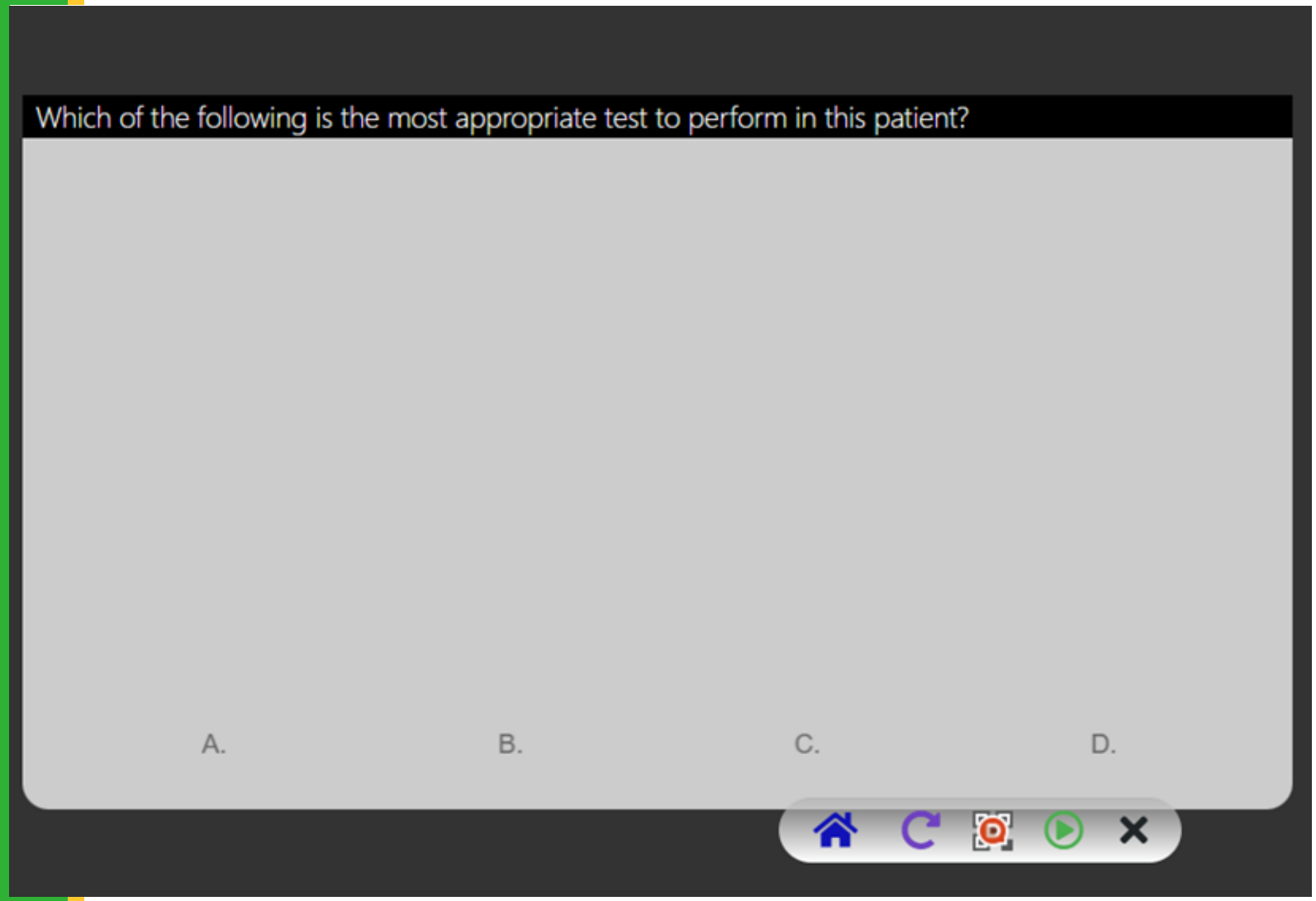

QUESTION 21

Which of the following is the most appropriate test to perform in this patient?

A. Biopsy
B. Mammography
C. Mammography and ultrasonography
D. Ultrasonography

QUESTION 21

- **Which of the following is the most appropriate test to perform in this patient?**

A. Biopsy

B. Mammography

C. Mammography and ultrasonography

D. **Ultrasonography**

QUESTION 21

- **Educational Objective:**
  - Evaluate a breast mass in a woman younger than 30 years.

A. Biopsy: invasive for low risk mass, especially if cystic

B. Mammography: low sensitivity with dense breast tissue

C. Mammography and ultrasonography: avoid radiation unless necessary

D. **<u>Ultrasonography</u>**

QUESTION 21

- **Educational Objective:**
  - Evaluate a breast mass in a woman younger than 30 years.
- **Evidence: Palpable Breast Abn**

TABLE 2: Rate of Malignancy of Palpable Breast Abnormalities With Probably Benign Ultrasound Features

Reference	Year	Age (y)		No. of Symptomatic Lesions[a]	No. of Cancers	Cancer Detection Rate	
		Mean	Range			%	95% CI
Giess et al. [30]	2012	31	15–68	336	3	0.9	—
Graf et al. [31]	2004	48	28–77	157	0	0.0	0–1.95[b]
Harvey et al. [28]	2009	34	12–88	375	1	0.3	0.01–1.5
Lehman et al. [5]	2012	35	30–39	64	0	0.0	—
Loving et al. [37]	2010	24	12–29	140	0	0.0	—
Park et al. [32]	2008	34	12–64	312	2	0.6	0–1.5
Smith et al. [33]	2008	—	< 25[c]	357	1	0.3	—

Note—Dash (—) indicates data were not reported and could not be deduced from available data.
[a]Symptomatic lesions with probably benign ultrasound features. All studies included only palpable lesions, except two studies (Lehman et al. [5] and Loving et al. [37]), which included focal breast signs or symptoms.
[b]One-sided 95% CI.
[c]Inclusion criteria. Range not provided.

Lehman CD, Lee AY, Lee CI. Imaging management of palpable breast abnormalities. AJR Am J Roentgenol. 2014 Nov;203(5):1142-53.

QUESTION 21

- **Educational Objective:**
  - Evaluate a breast mass in a woman younger than 30 years.

- **Key Point:**
  - For women younger than 30 years with a low-risk breast mass, ultrasonography is usually the only imaging required.

QUESTION 22

- A 64-year-old woman is evaluated during a posthospital visit for severe COPD with an FEV_1 of 30% of predicted.
- She has been admitted three times during the last year with acute exacerbations characterized by cough, increased purulent sputum production, and dyspnea.
- She is now at baseline of her exertional dyspnea and has no cough. She has already participated in a pulmonary rehabilitation program.

QUESTION 22

- She currently takes tiotropium, budesonide/formoterol, and albuterol.
- On physical examination, vital signs are normal. Oxygen saturation is 90% on 3 L/min of supplemental oxygen at rest and with exertion.
- Pulmonary examination reveals decreased breath sounds throughout. The remainder of the examination is noncontributory.

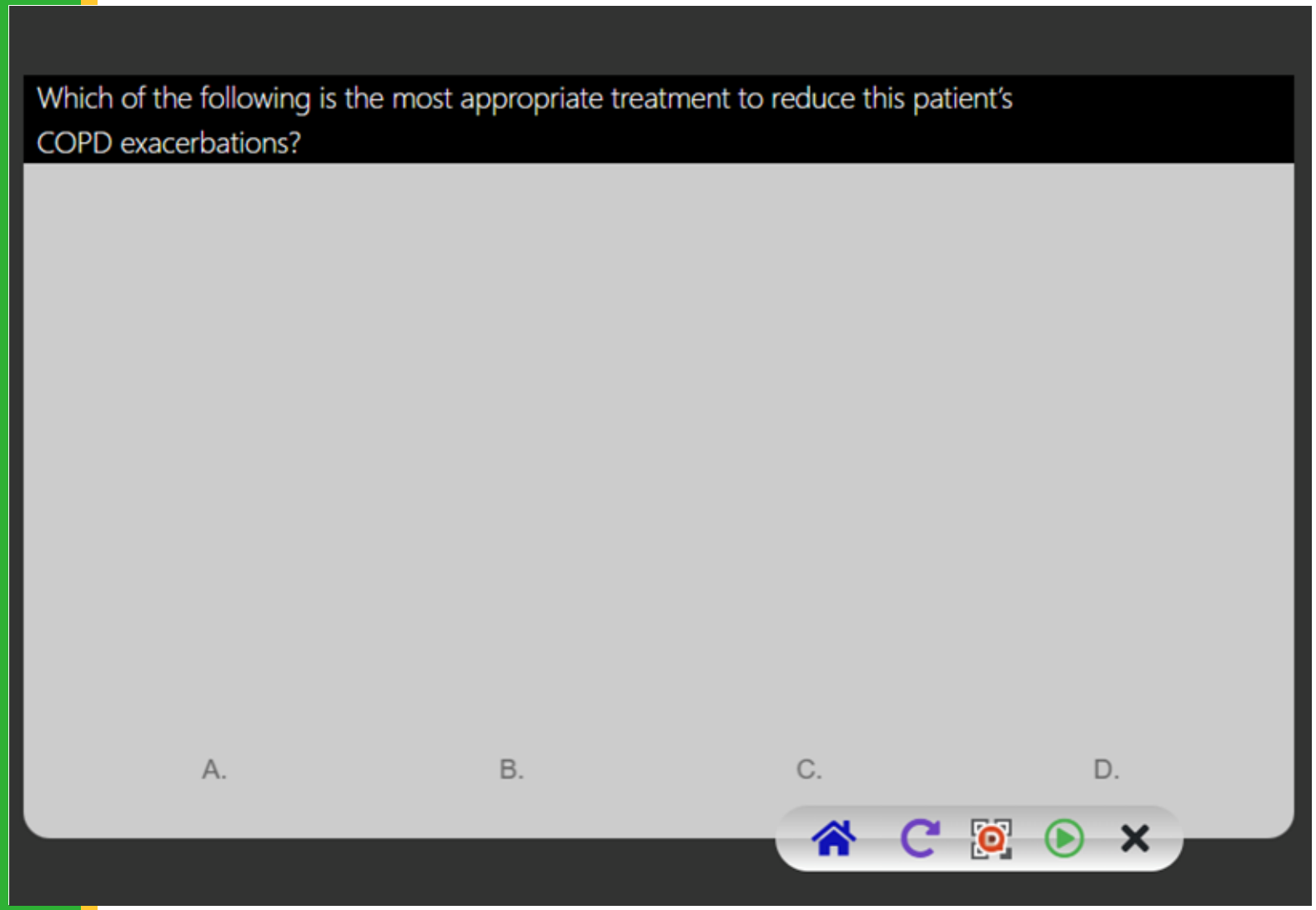

QUESTION 22

Which of the following is the most appropriate treatment to reduce this patient's COPD exacerbations?

A. Chronic low-dose oral glucocorticoid
B. Chronic macrolide therapy
C. Increase supplemental oxygen
D. Nebulized hypertonic saline

QUESTION 22

- **Which of the following is the most appropriate treatment to reduce this patient's COPD exacerbations?**

A. Chronic low-dose oral glucocorticoid

B. Chronic macrolide therapy

C. Increase supplemental oxygen

D. Nebulized hypertonic saline

QUESTION 22

Which of the following is the most appropriate treatment to reduce this patient's COPD exacerbations?

- LABA or LAMA
- LABA + LAMA or LABA + ICS
- LABA + LAMA + ICS
- LABA + LAMA + ICS + one of the following
  - roflumilast (if $FEV_1 < 50\%$ and chronic bronchitis)
  - azithromycin

QUESTION 22

- **Educational Objective:**
  - Treat a patient with a macrolide antibiotic to reduce frequent COPD exacerbations.

- **Key Point:**
  - In patients with severe COPD and frequent exacerbations, chronic macrolide therapy has been shown to decrease COPD exacerbations.

QUESTION 23

- A 72-year-old woman is evaluated during a routine visit. She has a 30-pack-year smoking history and quit 5 years ago.
- She has a history of mild COPD and breast cancer diagnosed 15 years ago, currently in remission. A chest radiograph from 5 years ago showed no signs of disease recurrence.

QUESTION 23

- Medications are albuterol and tiotropium inhalers.
- On physical examination, vital signs are normal. Lung examination reveals prolonged expiration and diminished breath sounds throughout.
- The breast examination is unremarkable.

QUESTION 23

- A screening low-dose chest CT scan shows a peripheral 9-mm solid pulmonary nodule in the left upper lobe and emphysema but no mediastinal or hilar lymphadenopathy and no pleural effusion.
- A PET/CT scan using fluorodeoxyglucose (FDG) is performed and the nodule is intensely hypermetabolic. There is no evidence of distant uptake.

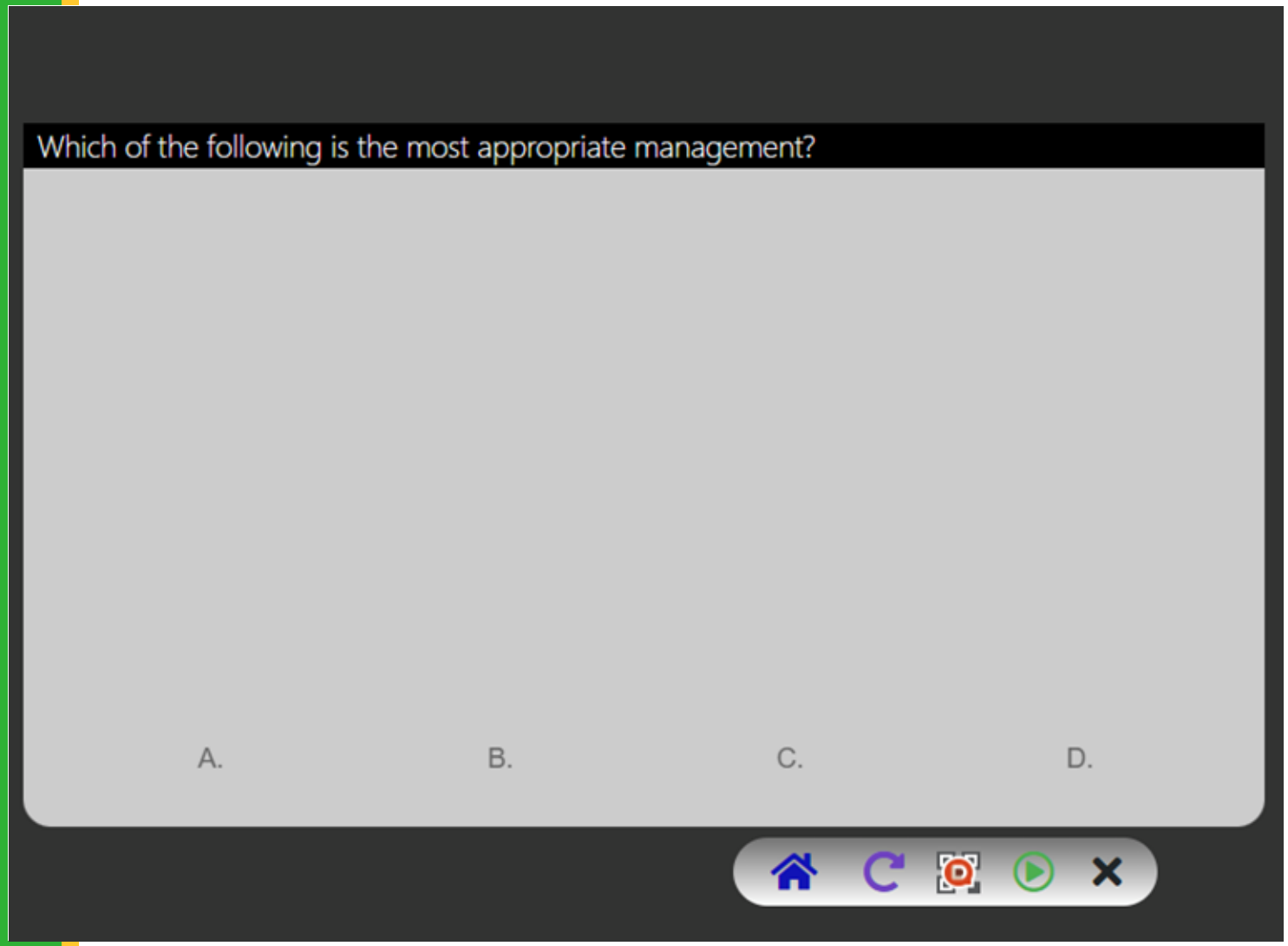

QUESTION 23

Which of the following is the most appropriate management?

A. Bronchoscopy with biopsy
B. Serial chest CT scans
C. Surgical wedge resection
D. Transthoracic needle aspiration

QUESTION 23

- **Which of the following is the most appropriate management?**

A. Bronchoscopy with biopsy

B. Serial chest CT scans

C. **Surgical wedge resection**

D. Transthoracic needle aspiration

QUESTION 23

- **Diagnosis**
  - High risk solitary pulmonary nodule

A. Bronchoscopy with biopsy: nodule is peripheral

B. Serial chest CT scans: inappropriate for high risk nodule

C. **Surgical wedge resection**

D. Transthoracic needle aspiration: option for intermediate risk nodules

QUESTION 23

- **Diagnosis**
  - High risk

Assessment Criteria	> 65%)
Clinical factors alone (determined by clinica judgment and/or use of validated model)[a]	oking, prior cancer, egular/spiculated pper-lobe location
FDG-PET scan results	metabolic nodule
Nonsurgical biopsy re (bronchoscopy or TTN	or malignancy
CT scan surveillance	nce of growth

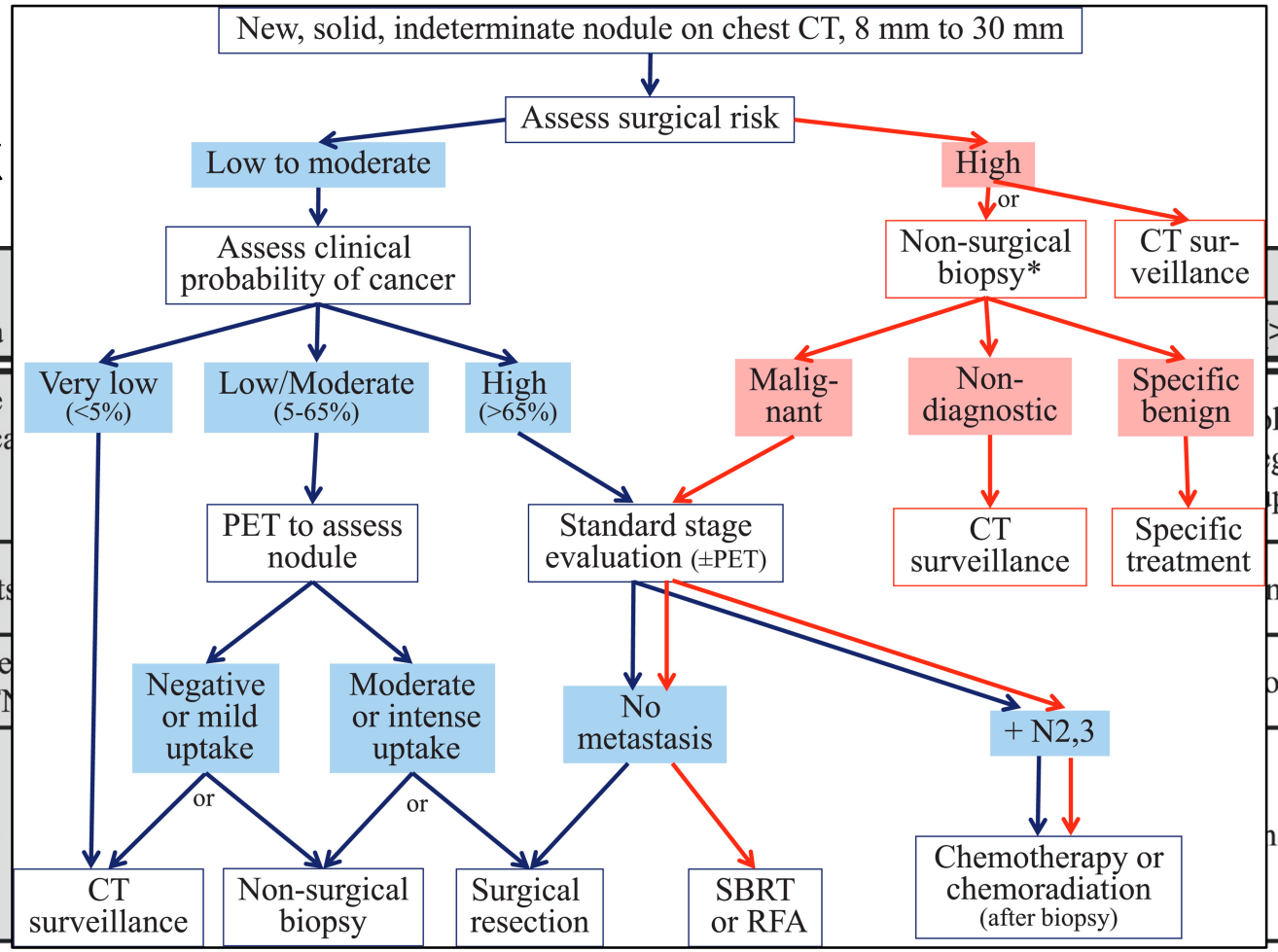

Gould MK et al. Evaluation of individuals with pulmonary nodules: when is it lung cancer? Diagnosis and management of lung cancer, 3rd ed: American College of Chest Physicians evidence-based clinical practice guidelines. Chest. 2013 May;143(5 Suppl):e93S-e120S.

QUESTION 23

- **Educational Objective:**
  - Evaluate a solitary pulmonary nodule in a patient at high risk for malignancy.

- **Key Point:**
  - Patients with a solid indeterminate lung nodule larger than 8 mm and high probability of malignancy should be staged using a PET/CT scan followed by definitive management.

QUESTION 24

- A 44-year-old man is evaluated during a follow-up visit for a 6-month history of low back pain. The pain worsens with standing and is relieved by lying down. He describes the pain as moderate aching.
- The pain does not radiate down the legs, and he has not had bowel or bladder dysfunction, fevers, leg weakness, night sweats, saddle anesthesia, or weight loss.

QUESTION 24

- The pain has been interfering with his ability to work. He participated in acupuncture, mindfulness-based stress reduction, and spinal manipulation, all of which provided only minimal relief.
- On physical examination, vital signs are normal. On palpation, bilateral paraspinal muscle tenderness is noted. The musculoskeletal and neurologic examinations are otherwise normal.

Which of the following is the most appropriate pharmacologic option for this patient?

A. B. C. D. E.

QUESTION 24

Which of the following is the most appropriate pharmacologic option for this patient?

A. Acetaminophen
B. Duloxetine
C. Hydrocodone
D. Ibuprofen
E. Tramadol

QUESTION 24

- **Which of the following is the most appropriate pharmacologic option for this patient?**

A. Acetaminophen

B. Duloxetine

C. Hydrocodone

D. Ibuprofen

E. Tramadol

QUESTION 24

- **Educational Objective:**
  - Treat chronic low back pain with an NSAID.

- **Key Point:**
  - For patients with chronic low back pain, clinicians and patients should initially select nonpharmacologic treatment; NSAIDs can be considered in patients who have had an inadequate response to nonpharmacologic therapy.

QUESTION 25

- A 78-year-old woman is evaluated for a 2-year history of gout with progressively more frequent and severe attacks.
- She currently has pain and swelling in the right second finger.
- History is also significant for hypertension, chronic kidney disease, nephrolithiasis, and type 2 diabetes mellitus.

QUESTION 25

- Medications are lisinopril, furosemide, metformin, and the maximal dose of febuxostat; she is allergic to allopurinol.
- On physical examination, vital signs are normal.

QUESTION 25

- The joint findings are shown.

QUESTION 25

- Laboratory studies show an erythrocyte sedimentation rate of 76 mm/h, a serum creatinine level of 1.5 mg/dL (132.6 µmol/L), and a serum urate level of 6.3 mg/dL (0.37 mmol/L).

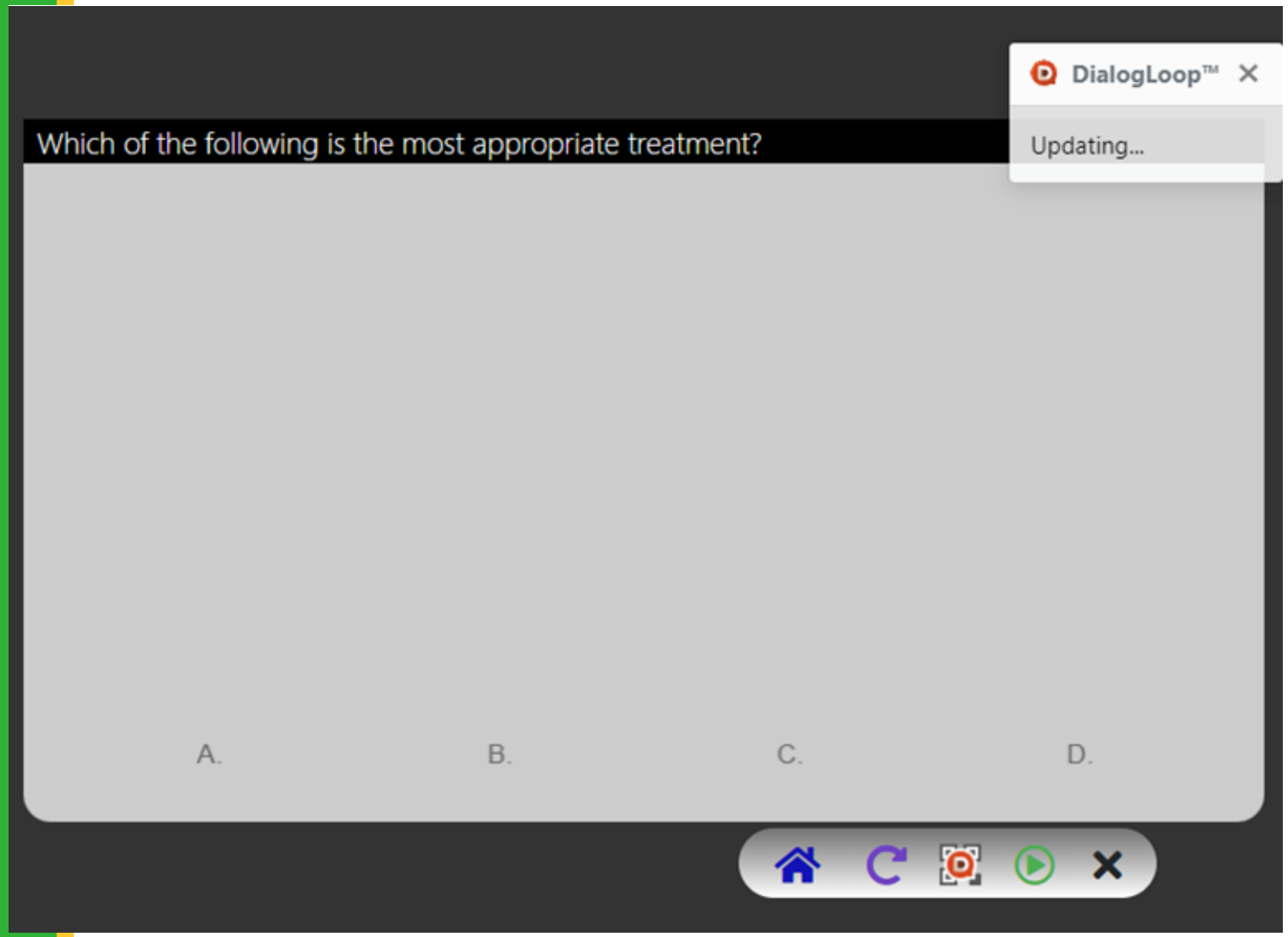

QUESTION 25

Which of the following is the most appropriate treatment?

A. Add probenecid
B. Stop febuxostat; begin pegloticase infusions
C. Stop lisinopril; begin losartan
D. Continue current treatment

QUESTION 25

- **Which of the following is the most appropriate treatment?**

A. Add probenecid

B. **Stop febuxostat; begin pegloticase infusions**

C. Stop lisinopril; begin losartan

D. Continue current treatment

QUESTION 25

- **Diagnosis**
  - Severe tophaceous gout

A. Add probenecid: contraindicated w/ eGFR < 60, hx nephrolithiasis

B. **Stop febuxostat; begin pegloticase infusions**

C. Stop lisinopril; begin losartan: mild uricosuric effect

D. Continue current treatment: unlikely to improve

QUESTION 25

- **Diagnosis**
  - Severe tophaceous gout

- **ACR 2020**

Table 5. When to consider switching to a new urate-lowering therapy (ULT) strategy*

Recommendation	PICO question	Certainty of evidence
For patients with gout taking their first XOI monotherapy at maximum-tolerated or FDA-indicated dose who are not at SU target and/or have continued frequent gout flares or nonresolving subcutaneous tophi, we conditionally recommend switching the first XOI to an alternate XOI agent over adding a uricosuric agent.	24	Very low
For patients with gout where XOI, uricosurics, and other interventions have failed to achieve SU target and who have frequent gout flares or nonresolving subcutaneous tophi, we strongly recommend switching to pegloticase over continuing current ULT.†	27	Moderate
For patients with gout for whom XOI, uricosurics, and other interventions have failed to achieve serum urate target and who have infrequent gout flares (<2 flares/year) and no tophi, we strongly recommend *against* switching to pegloticase over continuing current ULT.‡	27	Moderate

Strongly recommend | Conditionally recommend | Strongly recommend against | Conditionally recommend against

* PICO = population, intervention, comparator, outcomes; XOI = xanthine oxidase inhibitor; FDA = Food and Drug Administration.
† There is moderate certainty of evidence about the efficacy of the benefits, harms, and high certainty about the costs of pegloticase. For patients with high disease activity, the magnitude of potential benefits outweighs the harms and costs of the drug.
‡ For patients with minimal disease activity, the smaller potential benefits do not outweigh the harms and costs of the drug.

FitzGerald JD, Dalbeth N, Mikuls T, et al. 2020 American College of Rheumatology guideline for the management of gout. Arthritis Care Res (Hoboken). 2020;72:744-760. P

QUESTION 25

- **Educational Objective:**
  - Treat severe tophaceous gout.

- **Key Point:**
  - Pegloticase is strongly recommended for patients with severe recurrent and/or tophaceous gout that is intolerant or resistant to standard therapies.

Summary of learning points

- Asymptomatic first-degree atrioventricular block with bifascicular block does not require pacemaker implantation
- Topical retinoids are first-line treatment for comedonal acne
- Barrett esophagus with low-grade dysplasia should be treated with endoscopic ablation therapy
- Tadalafil is effective and the only FDA-approved option to treat both erectile dysfunction and LUTS from BPH

Summary of learning points

- Consider left heart catheterization and direct measurement when there is discrepancy in severity of aortic stenosis
- Add dexamethasone to the empiric treatment of high risk bacterial meningitis
- We likely underuse bisphosphonates in the treatment of osteoporosis
- Advance uricosuric therapy when symptoms of gout persist despite urocosuric therapy