

Lower Extremity DVT Examination

Woo J Moon DO, FACP. Mercy Hospital St. Louis

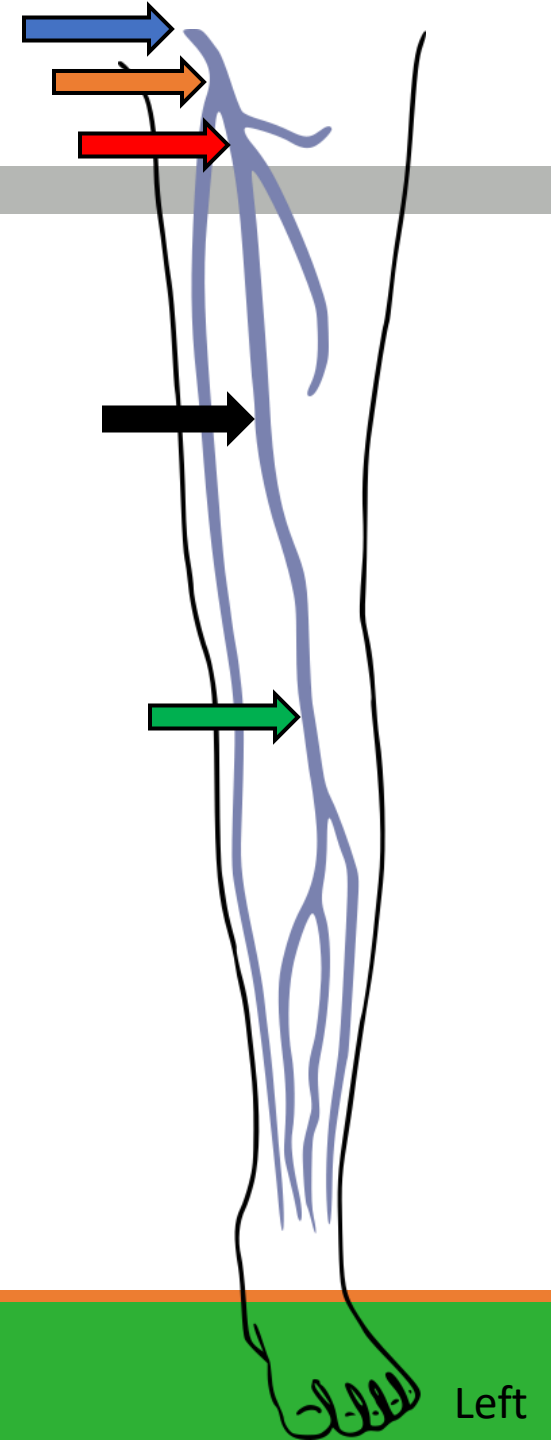
Ian R Ross MD, FACP. Washington University in St. Louis & John Cochran VA Medical Center

Disclosures

- None

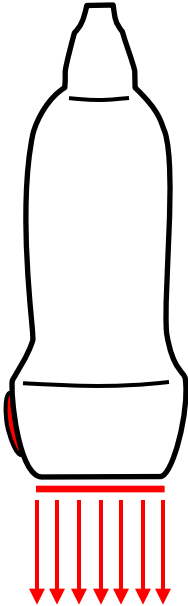
Lower Extremity Venous Anatomy

- Key Areas
 - Common femoral vein
 - Saphenofemoral junction
 - Deep femoral and femoral vein junction
 - Femoral vein and adductor canal
 - Popliteal vein and trifurcation

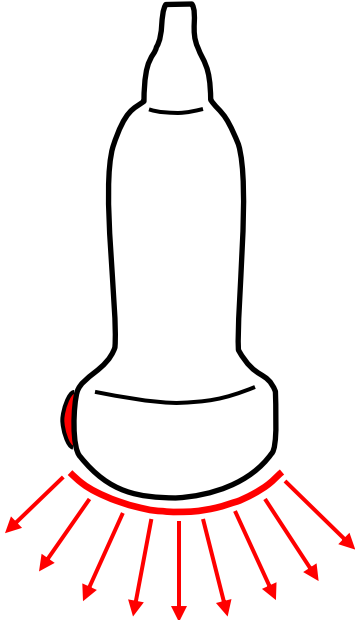


Transducer Selection

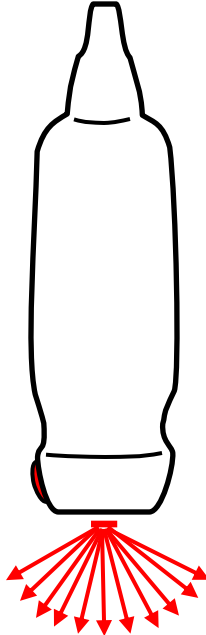
Linear



Curvilinear



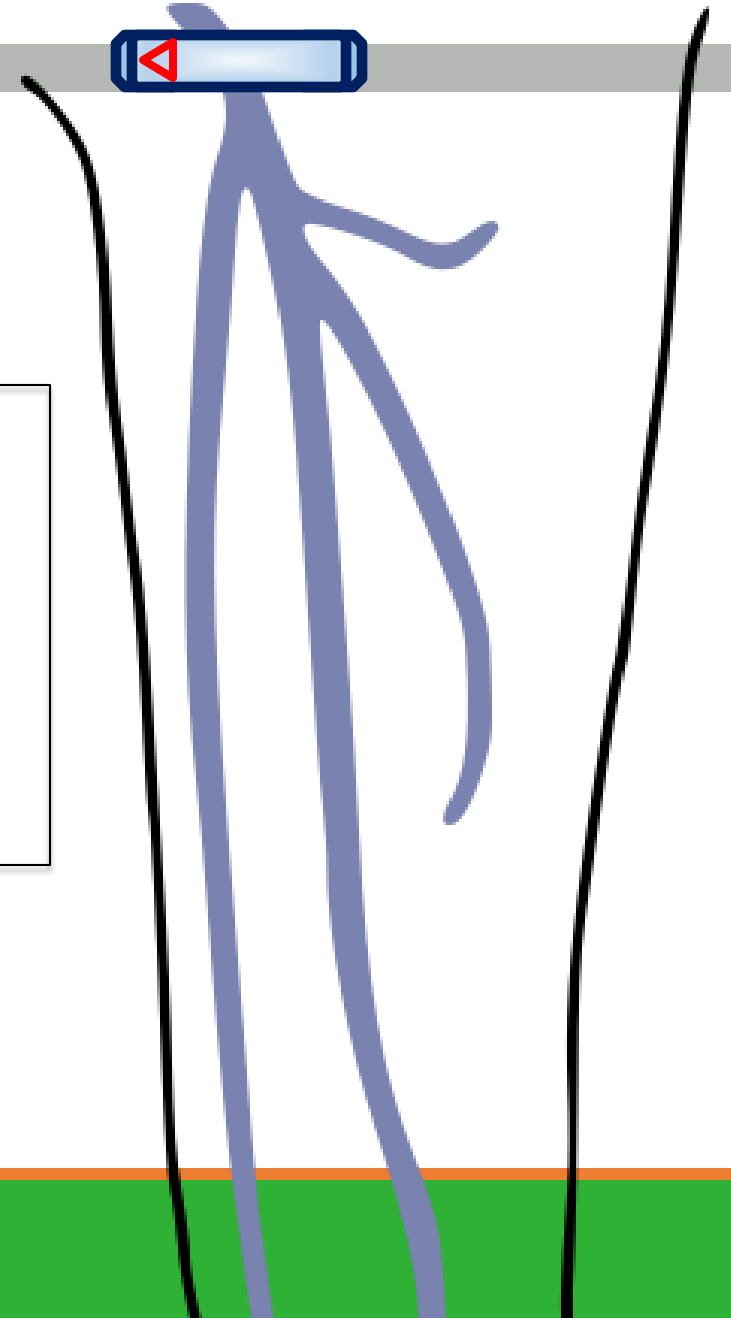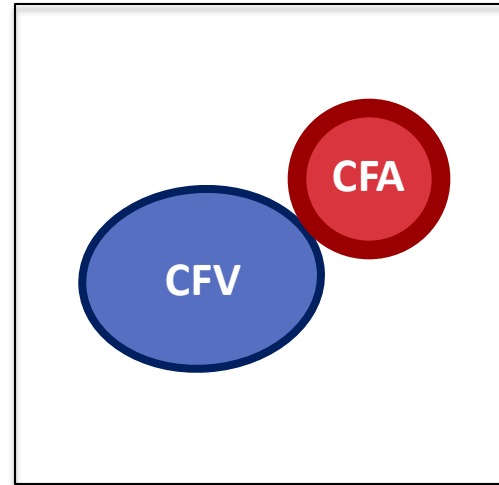
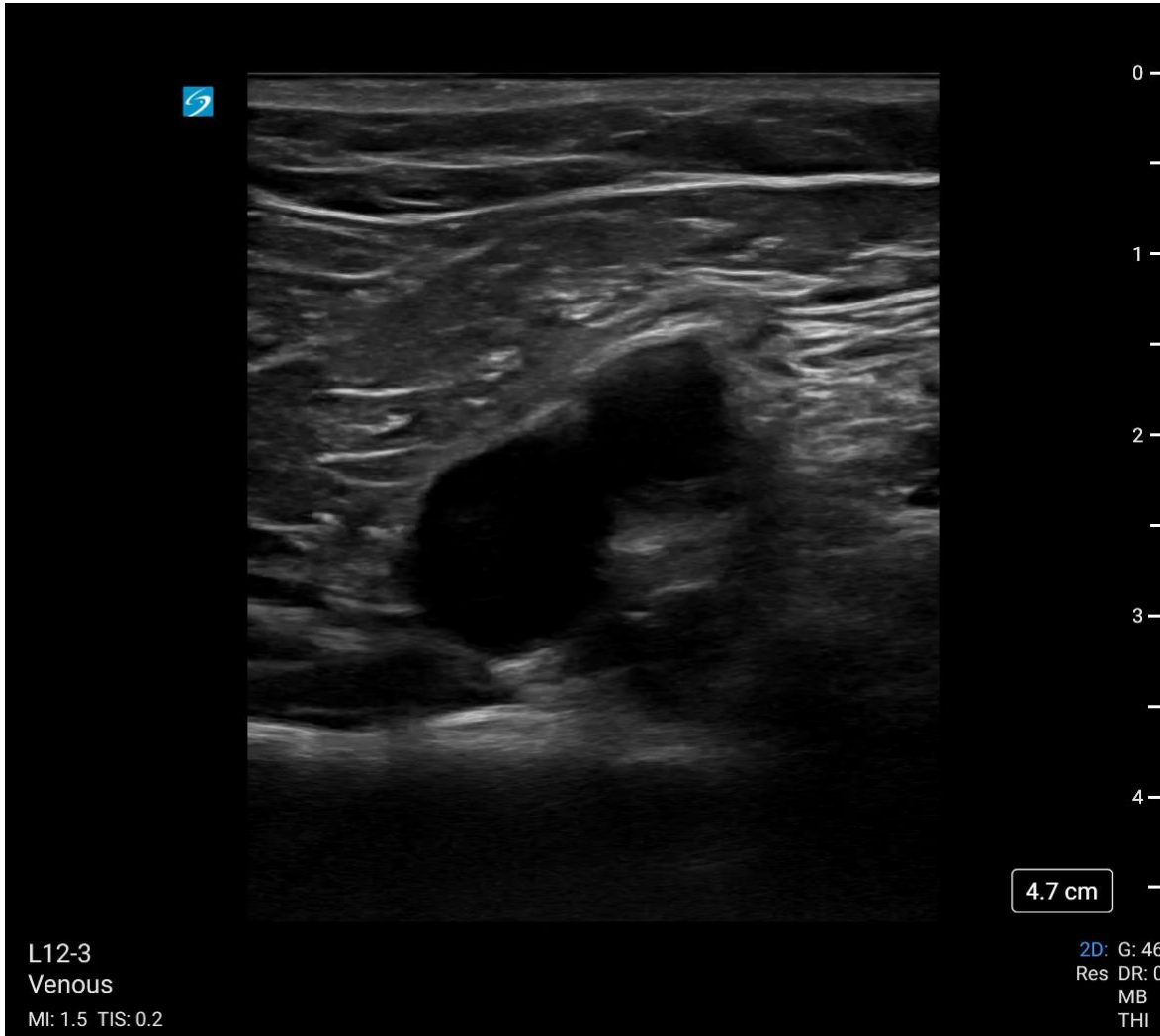Phased array



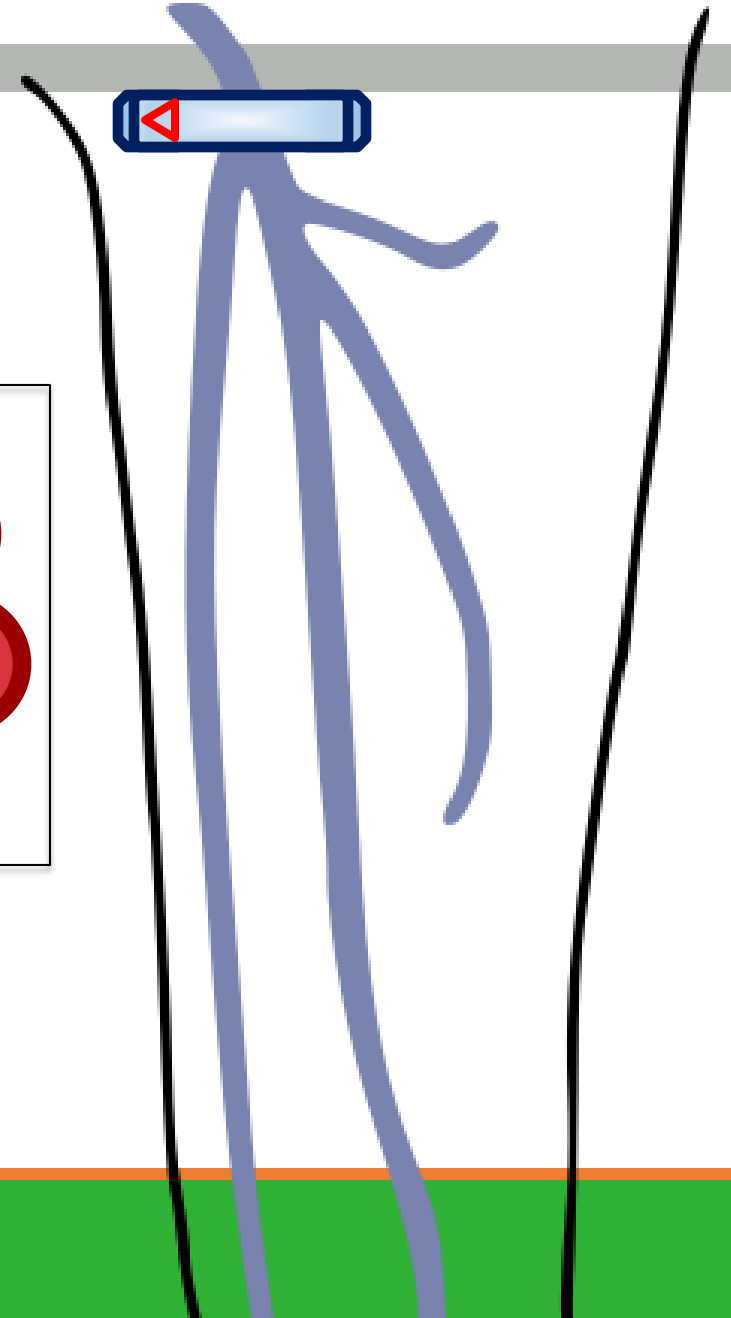
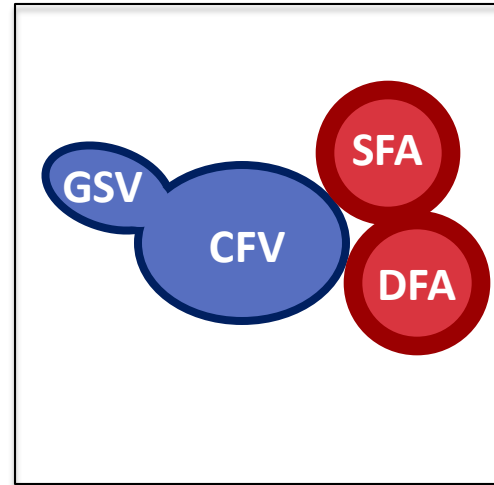
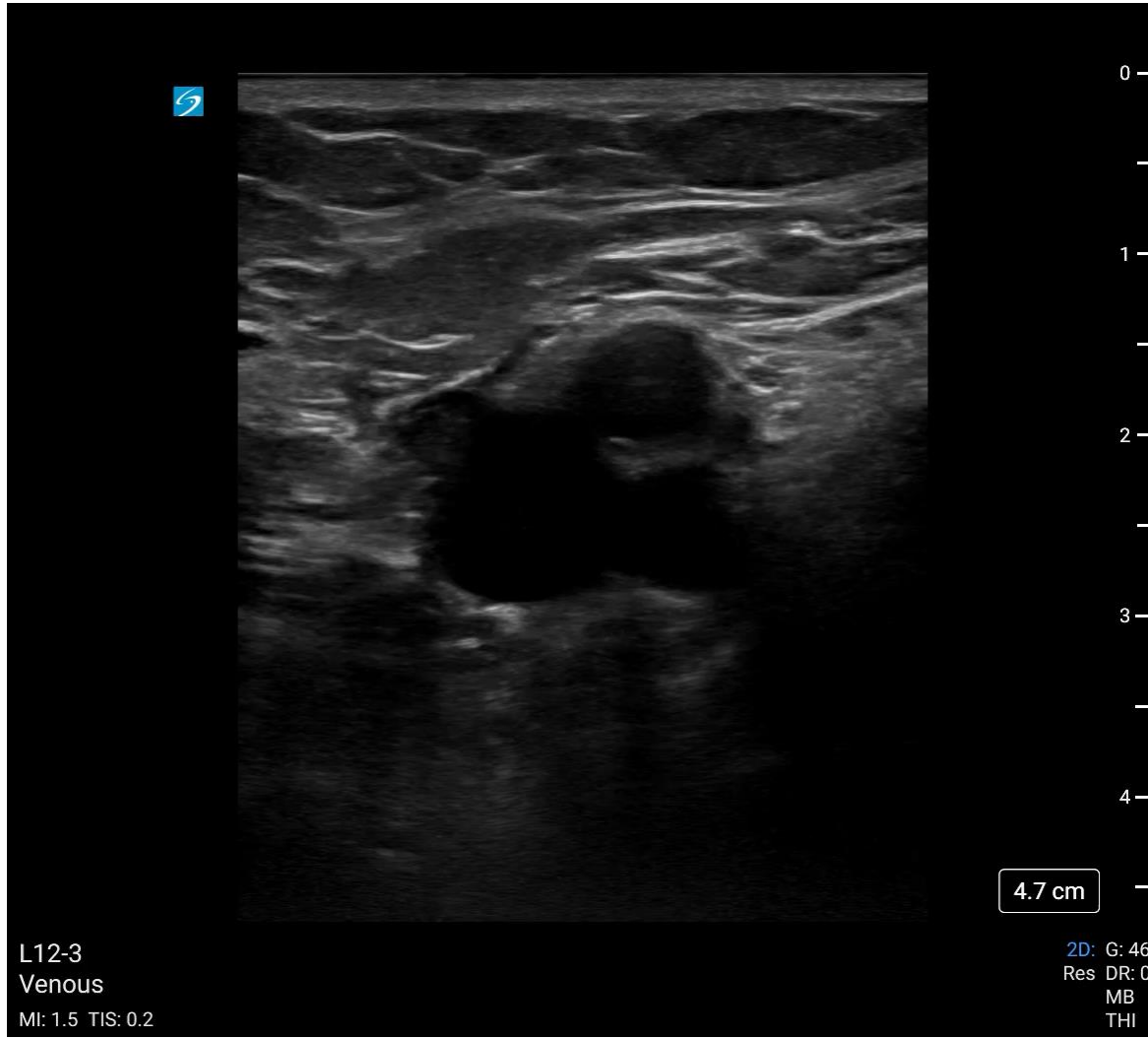Extended Compression Ultrasound Exam

- Start above the inguinal ligament (external iliac vein & artery)
- Hold the transducer perpendicular to the skin, marker to the right
- Slide the probe caudally, compressing every 1 to 2cm
 - Don't compress if thrombus is visualized
 - Artery should deform with compression
- End exam at the popliteal region

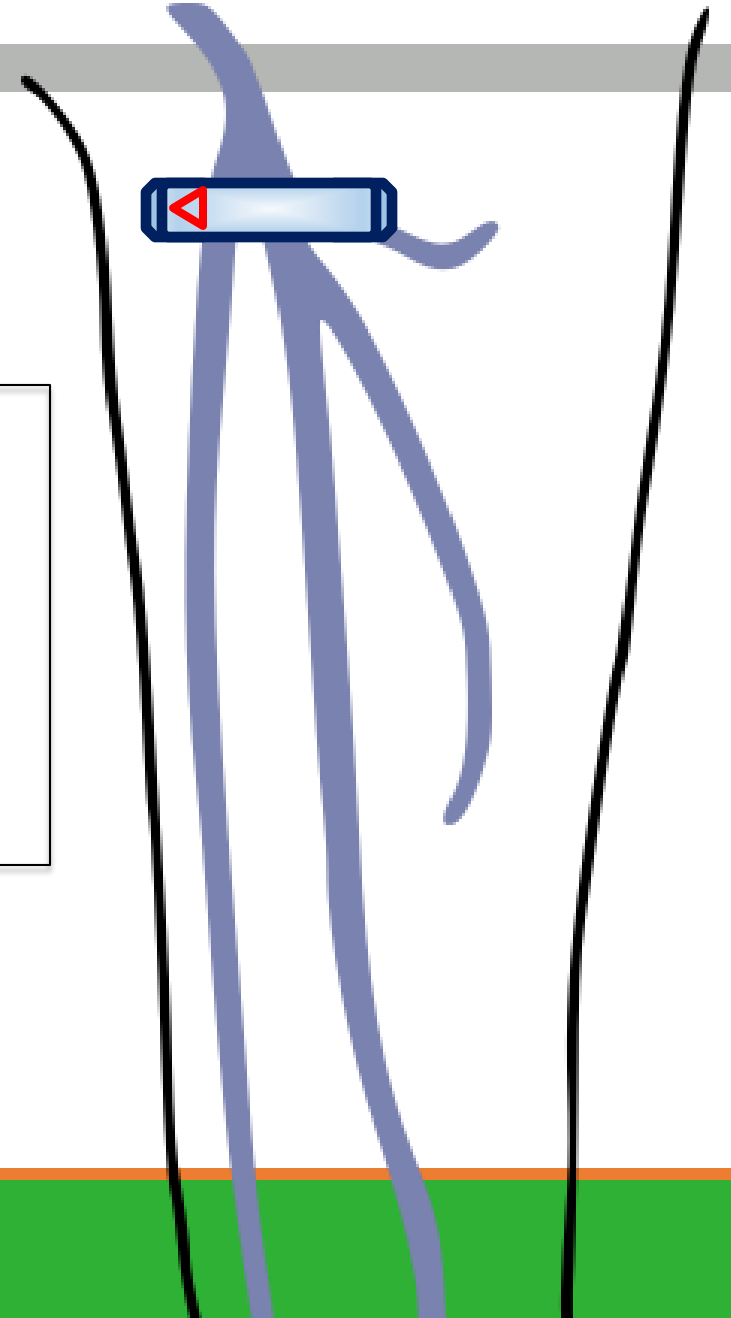
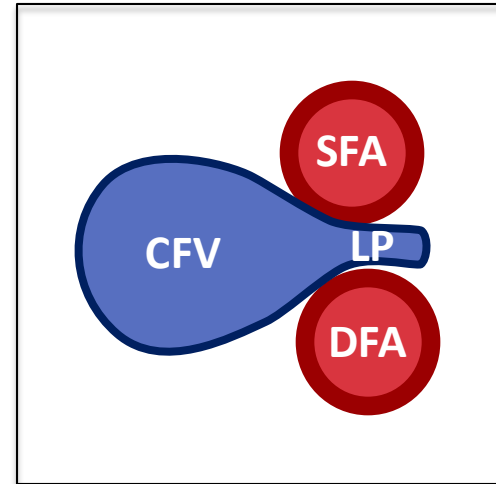
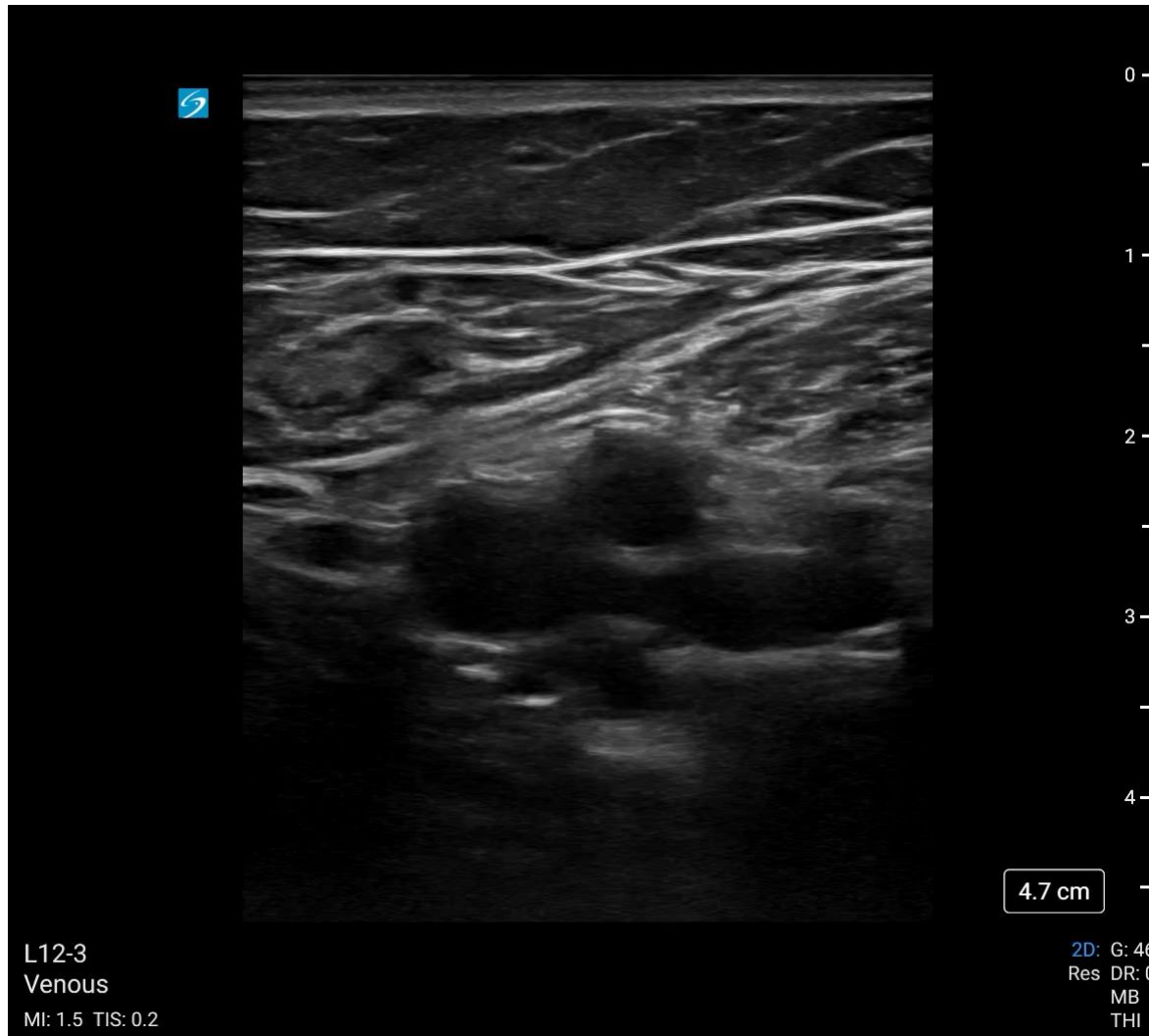Common Femoral Vein



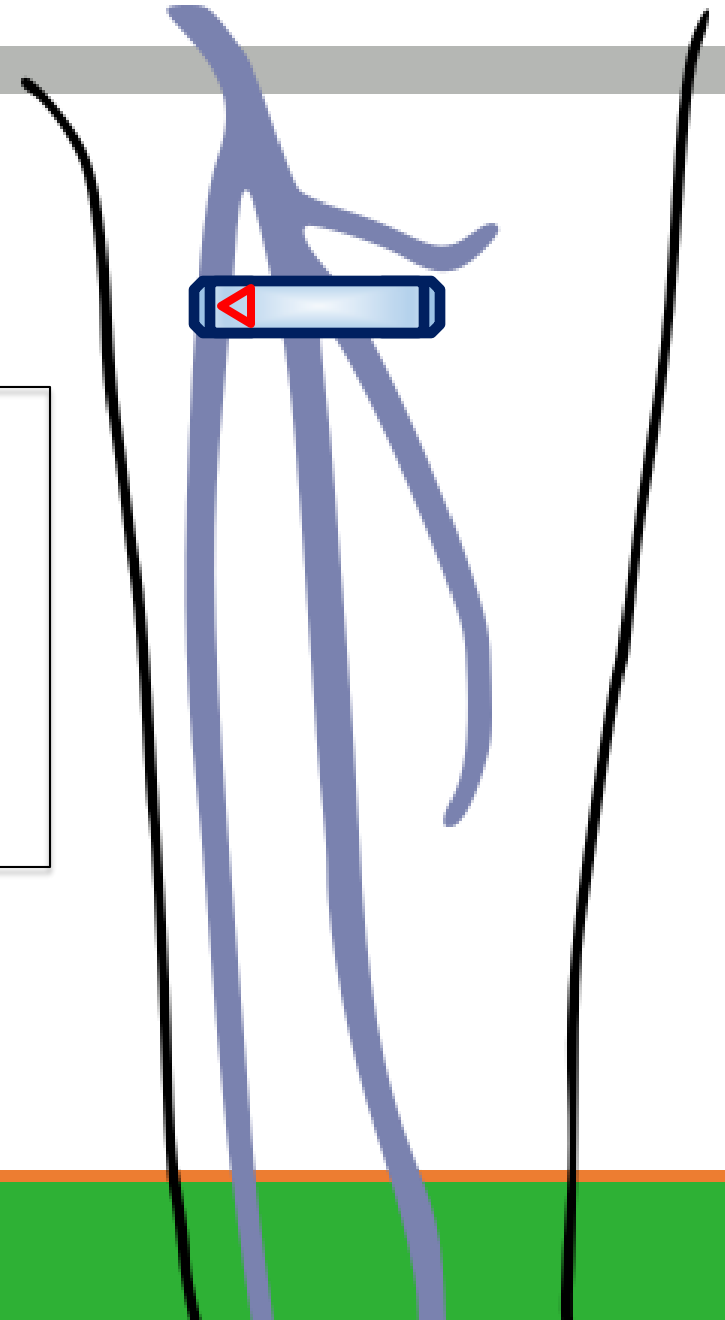
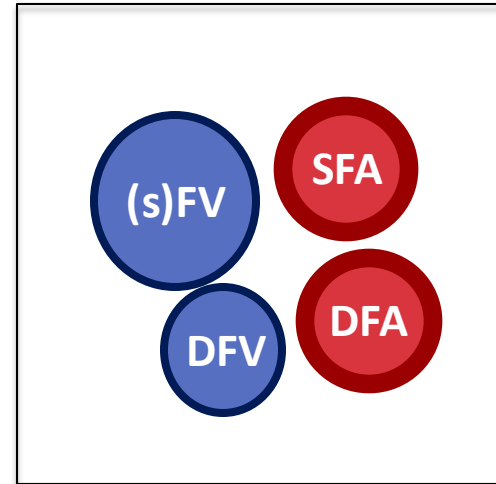
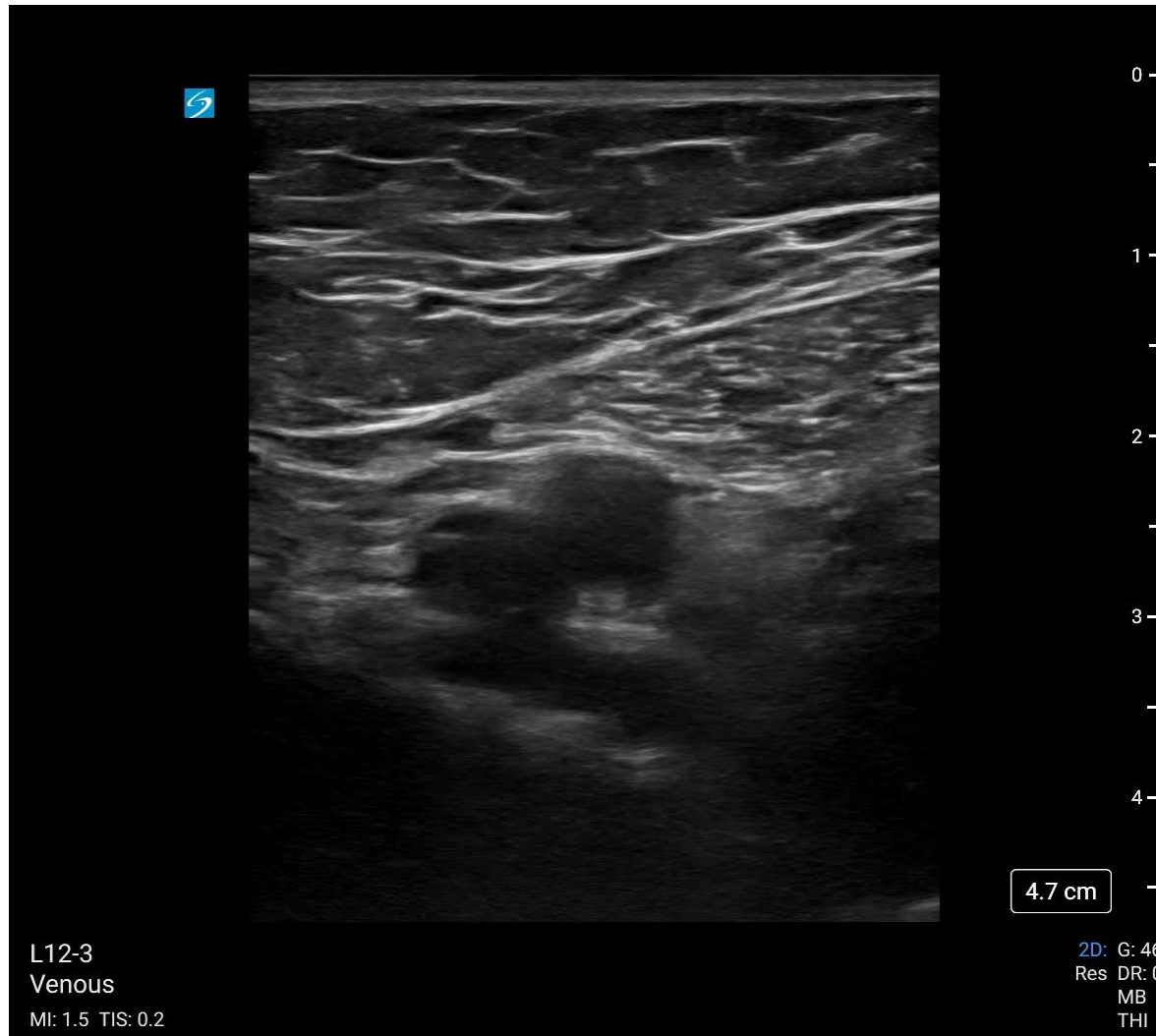
Great Saphenous Vein Junction



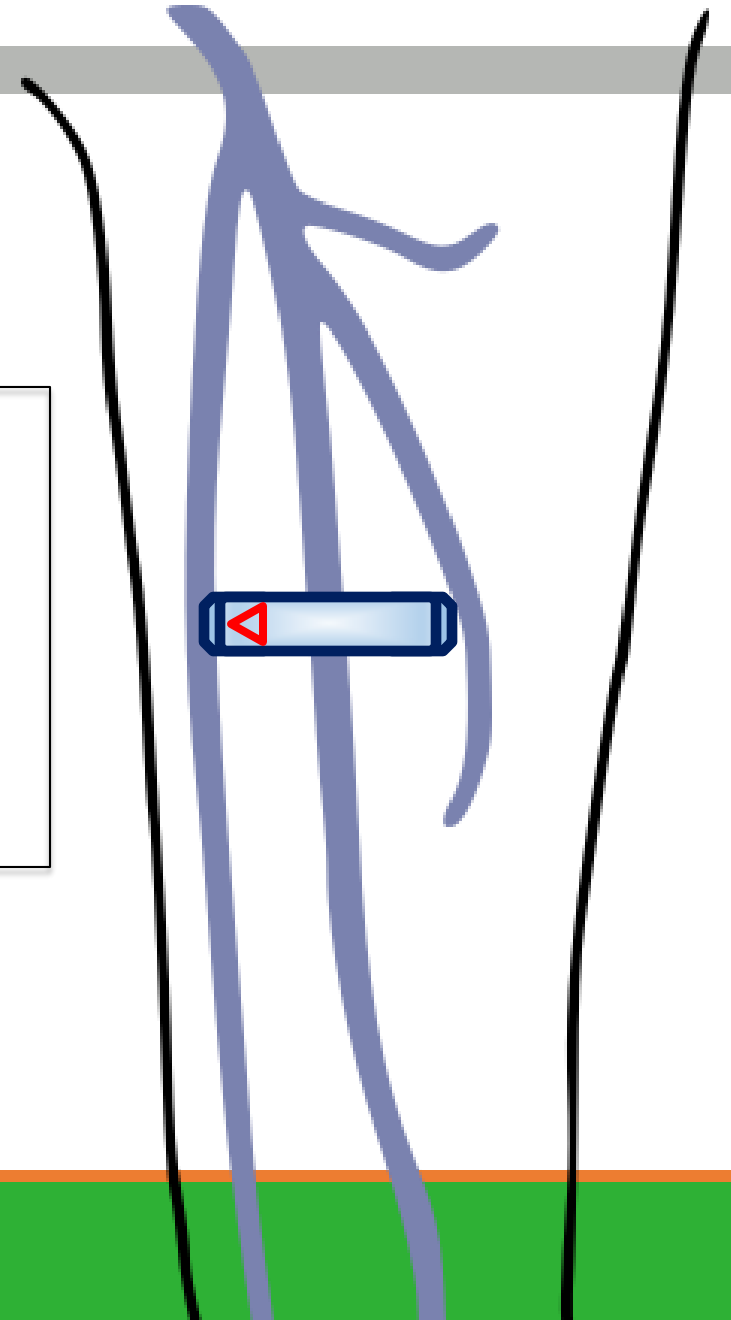
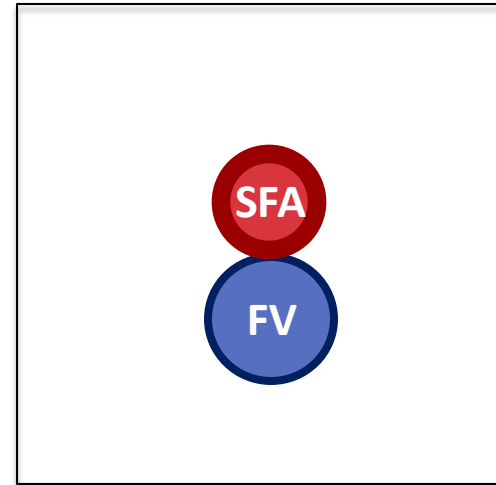
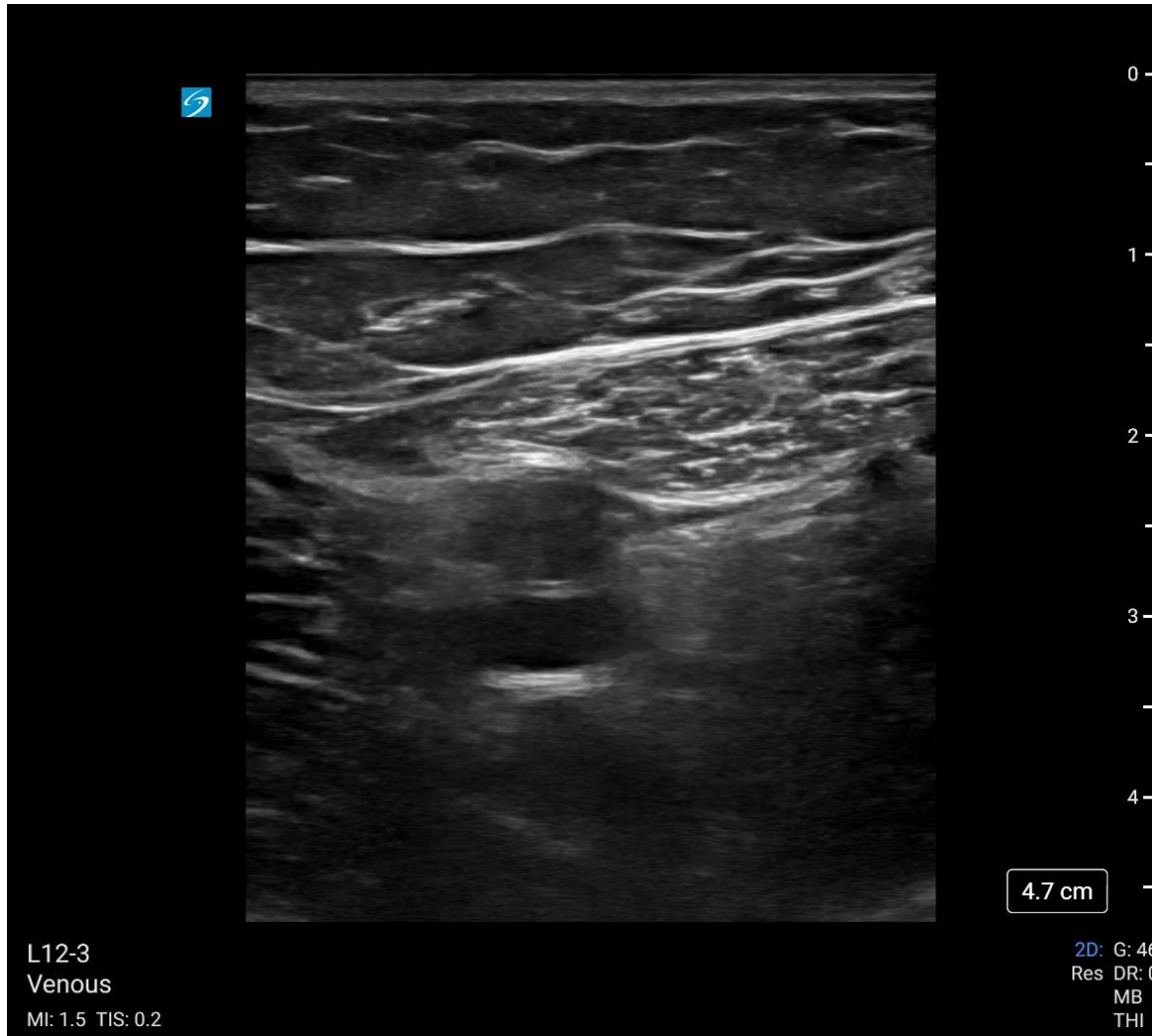Lateral Perforator (May Be Seen)



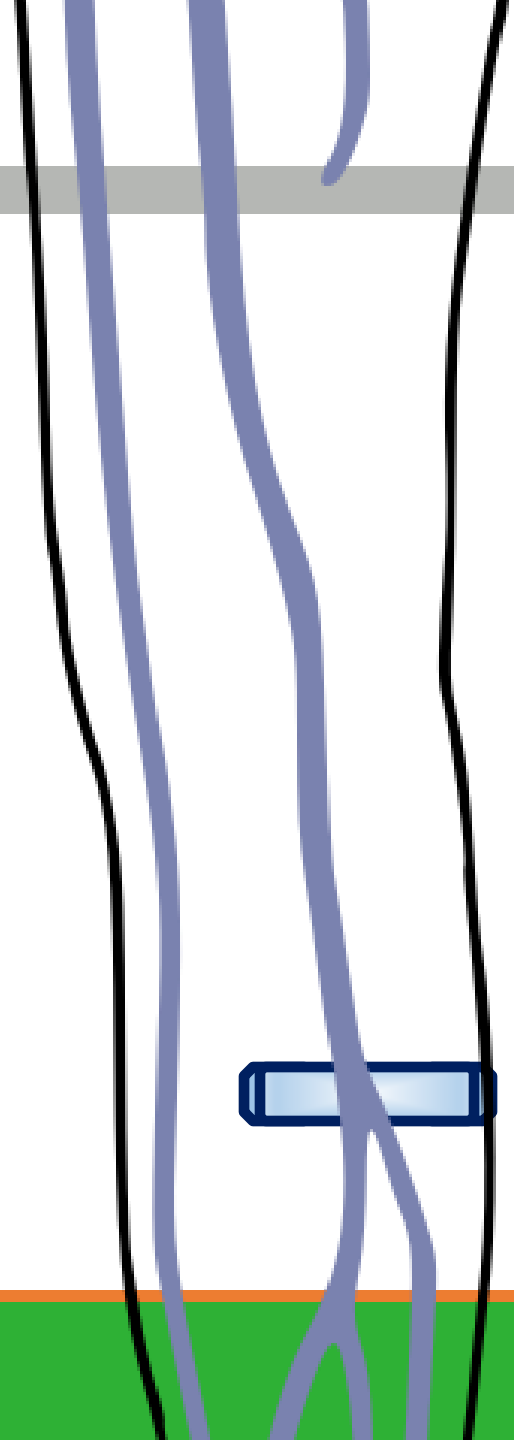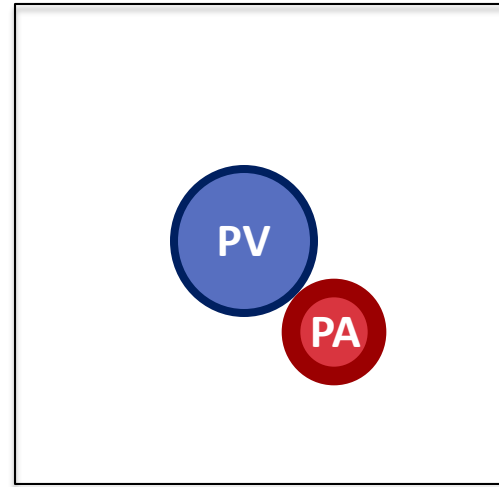
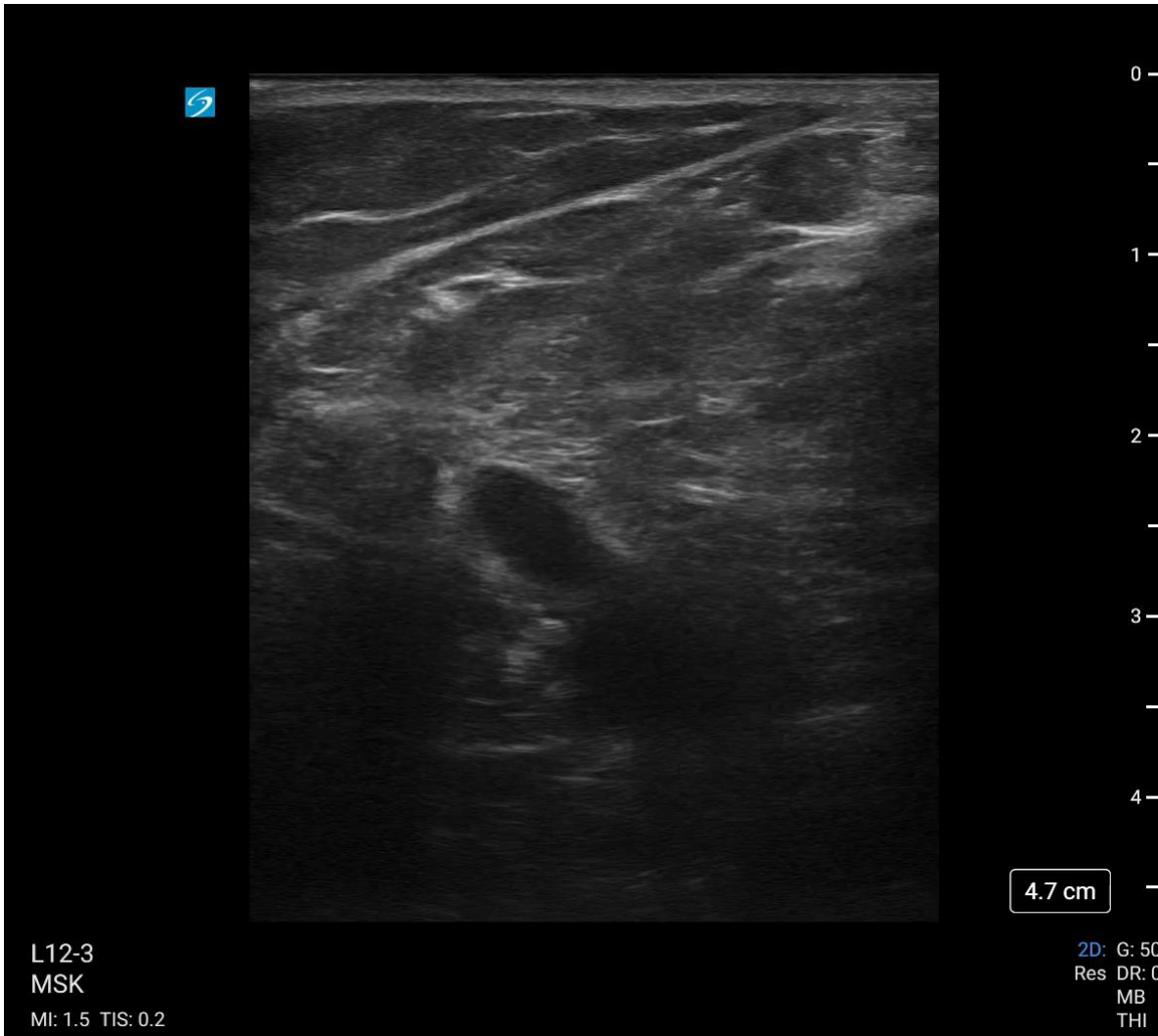Deep Femoral & Femoral Vein



Mid Femoral Vein



Popliteal Vein



References

1. Lutsey PL, Zakai NA. Epidemiology and prevention of venous thromboembolism. *Nat Rev Cardiol* 2023;20(4):248–62.
2. Girard P, Sanchez O, Leroyer C, et al. Deep venous thrombosis in patients with acute pulmonary embolism: prevalence, risk factors, and clinical significance. *Chest* 2005;128(3):1593–600.
3. Soni MD MS NJ, Arntfield MD FRCPC R, Kory MD MPA P. *Point of Care Ultrasound*. 2nd ed. St. Louis, MO: Elsevier; 2019.
4. Kahn SR, de Wit K. Pulmonary Embolism. *N Engl J Med* 2022;387(1):45–57.
5. Smith SB, Geske JB, Maguire JM, Zane NA, Carter RE, Morgenthaler TI. Early anticoagulation is associated with reduced mortality for acute pulmonary embolism. *Chest* 2010;137(6):1382–90.
6. McGee MD S. *Evidence-Based Physical Diagnosis*. 5th ed. Philadelphia: Elsevier; 2021.
7. Silveira PC, Ip IK, Goldhaber SZ, Piazza G, Benson CB, Khorasani R. Performance of wells score for deep vein thrombosis in the inpatient setting. *JAMA Intern Med* 2015;175(7):1112–7.
8. Wells PS, Anderson DR, Bormanis J, et al. Value of assessment of pretest probability of deep-vein thrombosis in clinical management. *Lancet* 1997;350(9094):1795–8.
9. Kearon C, Julian JA, Newman TE, Ginsberg JS. Noninvasive diagnosis of deep venous thrombosis. McMaster Diagnostic Imaging Practice Guidelines Initiative. *Ann Intern Med* 1998;128(8):663–77.
10. Goodacre S, Sampson F, Thomas S, van Beek E, Sutton A. Systematic review and meta-analysis of the diagnostic accuracy of ultrasonography for deep vein thrombosis. *BMC Med Imaging* 2005;5:6.
11. *Ultrasound Guidelines: Emergency, Point-of-Care and Clinical Ultrasound Guidelines in Medicine*. *Ann Emerg Med* 2017;69(5):e27–54.
12. Kory PD, Pellecchia CM, Shiloh AL, Mayo PH, DiBello C, Koenig S. Accuracy of ultrasonography performed by critical care physicians for the diagnosis of DVT. *Chest* 2011;139(3):538–42.
13. Fischer EA, Kinnear B, Sall D, et al. Hospitalist-Operated Compression Ultrasonography: a Point-of-Care Ultrasound Study (HOCUS-POCUS). *J Gen Intern Med* 2019;34(10):2062–7.
14. Mumoli N, Vitale J, Giorgi-Pierfranceschi M, et al. General Practitioner-Performed Compression Ultrasonography for Diagnosis of Deep Vein Thrombosis of the Leg: A Multicenter, Prospective Cohort Study. *Ann Fam Med* 2017;15(6):535–9.
15. Needleman L, Cronan JJ, Lilly MP, et al. Ultrasound for lower extremity deep venous thrombosis: multidisciplinary recommendations from the society of radiologists in ultrasound consensus conference. *Circulation* 2018;137(14):1505–15.
16. Bernardi E, Camporese G, Büller HR, et al. Serial 2-point ultrasonography plus D-dimer vs whole-leg color-coded Doppler ultrasonography for diagnosing suspected symptomatic deep vein thrombosis: a randomized controlled trial. *JAMA* 2008;300(14):1653–9.
17. Cogo A. Distribution of thrombosis in patients with symptomatic deep vein thrombosis. *Arch Intern Med* 1993;153(24):2777.
18. Tabbutt M, Ebersole N, Icken L, Jones R, Gramer D. Two-point Compression Ultrasound Technique Risks Missing Isolated Femoral Vein DVTs. *West J Emerg Med* 2022;23(4):597–600.
19. Maki DD, Kumar N, Nguyen B, Langer JE, Miller WT, Geftter WB. Distribution of thrombi in acute lower extremity deep venous thrombosis: implications for sonography and CT and MR venography. *AJR Am J Roentgenol* 2000;175(5):1299–301.
20. Caronia J, Sarzynski A, Tofighi B, et al. Resident performed two-point compression ultrasound is inadequate for diagnosis of deep vein thrombosis in the critically ill. *J Thromb Thrombolysis* 2014;37(3):298–302.
21. Nunn KP, Thompson PK. Towards evidence based emergency medicine: best BETs from the Manchester Royal Infirmary. Using the ultrasound compression test for deep vein thrombosis will not precipitate a thromboembolic event. *Emerg Med J* 2007;24(7):494–5.
22. Barrosse-Antle ME, Patel KH, Kramer JA, Baston CM. Point-of-Care Ultrasound for Bedside Diagnosis of Lower Extremity DVT. *Chest* 2021;160(5):1853–63.